

Positional right hip and thigh pain

Taylor J. Stone · Jenny T. Bencardino ·
Zehava S. Rosenberg

Published online: 10 December 2014
© ISS 2014

Skeletal Radiology - Test Yourself

Part 1

Question: Positional right hip and thigh pain.

History: 76-year-old woman with metastatic lung cancer and right hip and thigh pain that is provoked by walking and relieved by lying supine. (Figs. 1, 2, 3 and 4)

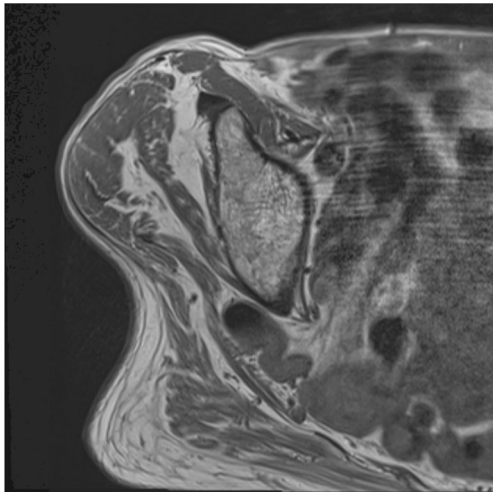


Fig. 1 Transaxial short TR/TE

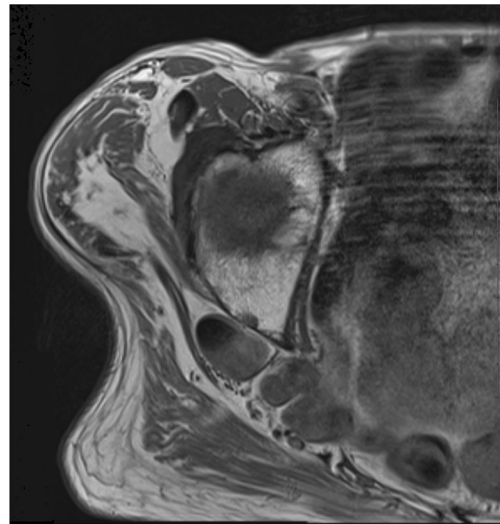


Fig. 2 Transaxial short TR/TE

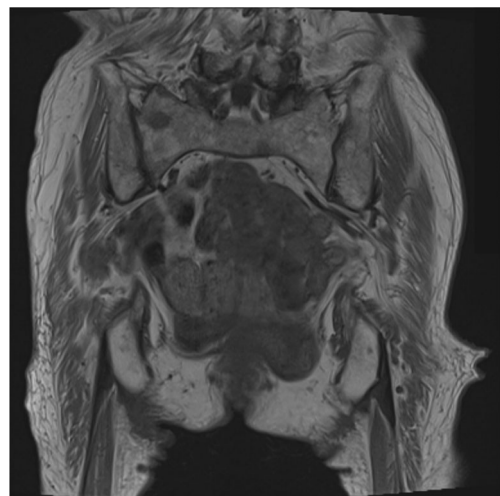


Fig. 3 Coronal short TR/TE

The diagnosis can be found at doi:[10.1007/s00256-014-2077-1](https://doi.org/10.1007/s00256-014-2077-1)

T. J. Stone (✉) · J. T. Bencardino · Z. S. Rosenberg
Hospital for Joint Diseases, New York University Langone Medical
Center, New York, NY 10003, USA
e-mail: taylor.stone.md@gmail.com

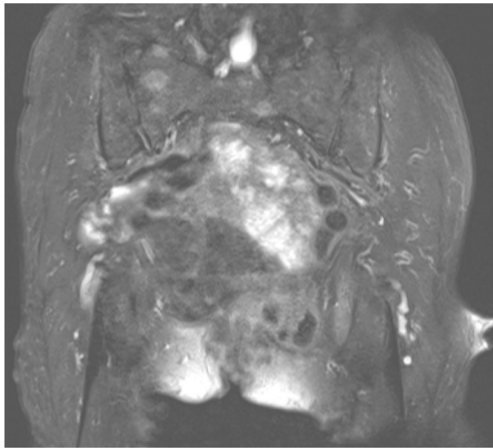


Fig. 4 Coronal fat-suppressed fluid-sensitive fast spin echo