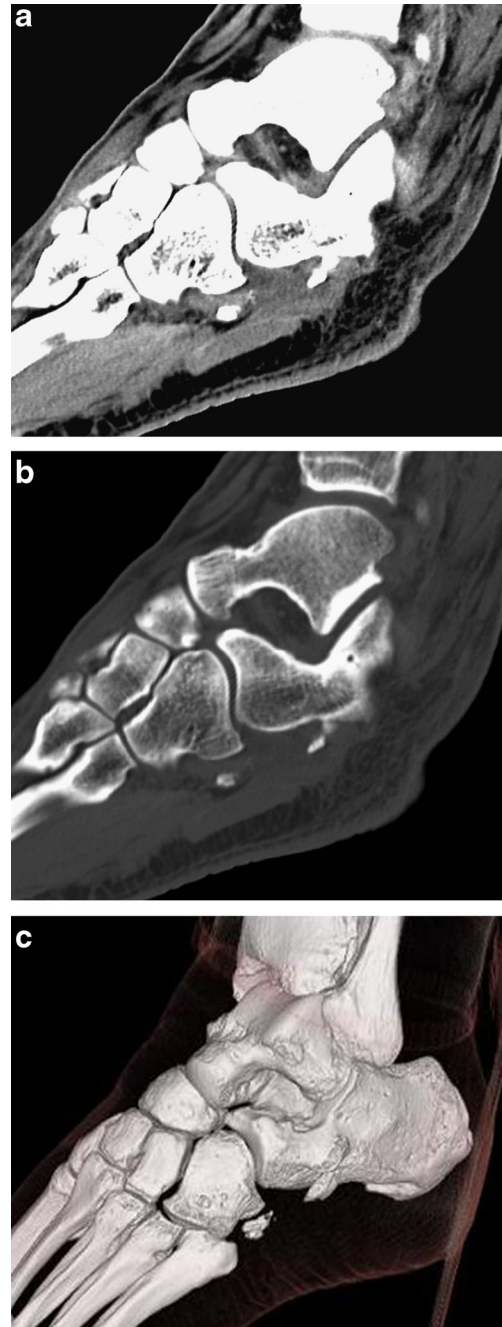


## Lateral midfoot pain

Pamela Habib · Joseph S. Yu

Published online: 10 June 2014  
© ISS 2014

History: A 35-year-old male presented three weeks after a skiing accident. Figures 1 and 2.



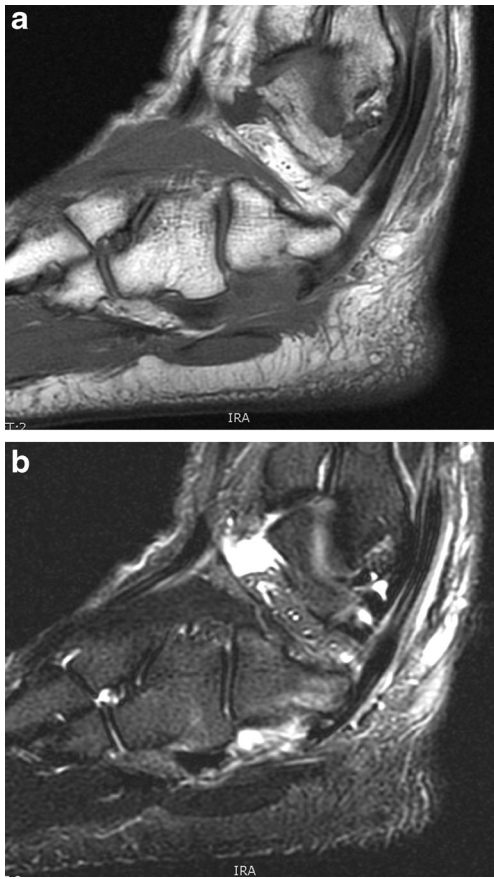
**Fig. 1** Computed tomography images.

---

The diagnosis can be found at doi: [10.1007/s00256-014-1934-2](https://doi.org/10.1007/s00256-014-1934-2)

P. Habib · J. S. Yu  
The Ohio State University Wexner Medical Center, 395 West 12th  
Avenue, Columbus, OH 43210, USA

J. S. Yu (✉)  
Department of Radiology, 481 Doan Tower, 395 West 12th Avenue,  
Columbus, OH 43210, USA  
e-mail: joseph.yu@osumc.edu



**Fig. 2** Sagittal T1-weighted and STIR MR images.