

Dorsal wrist pain and swelling post trauma

John Vedelago • Elizabeth Dick • Miny Walker •
Afshin Alavi • Monica Khanna • Wladyslaw Gedroyc

Published online: 11 January 2013
© ISS 2013

A 29-year-old male presented immediately following a cyclist versus car accident with right wrist pain and swelling. The swelling was prominent, and located primarily over the dorsal aspect of the wrist and hand. A CT image from a study at the time of presentation is shown in Fig. 1, and a sagittal T1-weighted MRI 4 days after injury in Fig. 2. What is the cause of the swelling at the dorsal aspect of the wrist and hand?

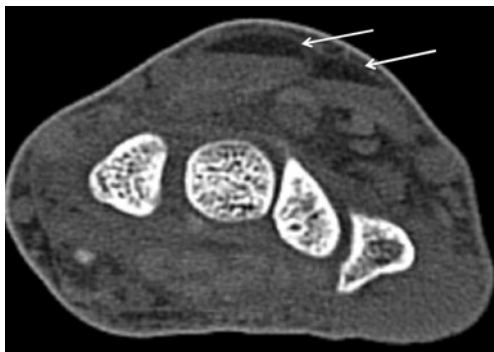


Fig. 1 CT image from a study at the time of presentation

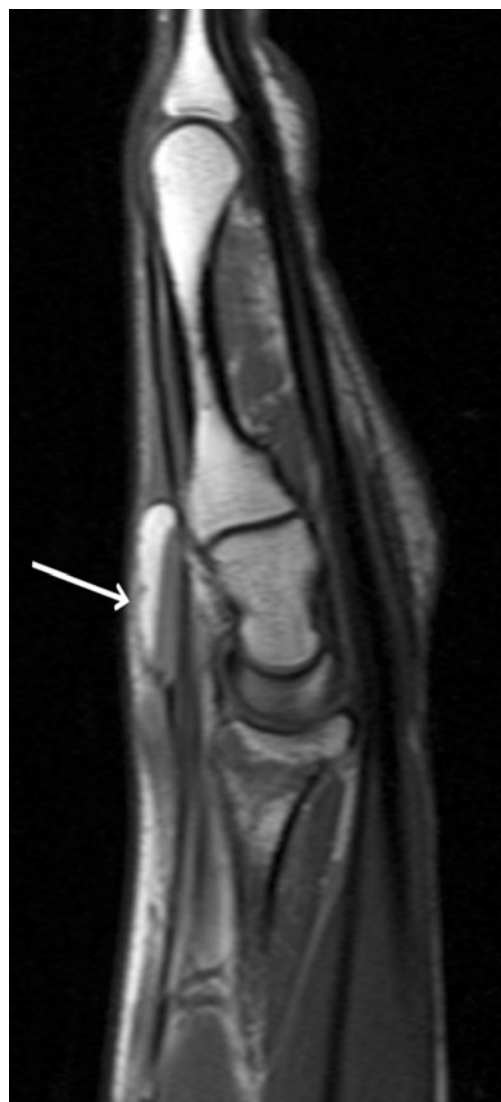

Fig. 2 Sagittal T1-weighted MRI 4 days after injury

The diagnosis can be found at doi: 10.1007/s00256-012-1570-7

J. Vedelago (✉) • E. Dick • M. Walker • A. Alavi • M. Khanna •
W. Gedroyc
Department of Radiology, St. Mary's Hospital, Praed Street,
London W2 1NY, UK
e-mail: john.vedelago@imperial.nhs.uk