

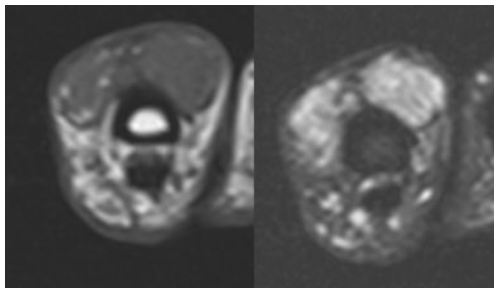
## Parachordoma/myoepithelioma

Sayed Ali · Bing Leng · William R. Reinus ·  
Natalya Khilko · Jasvir S. Khurana

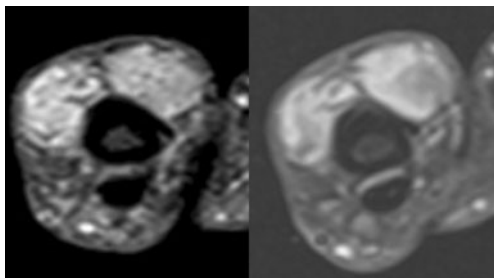
Received: 16 January 2012 / Revised: 29 March 2012 / Accepted: 5 April 2012 / Published online: 23 May 2012  
© ISS 2012

### History

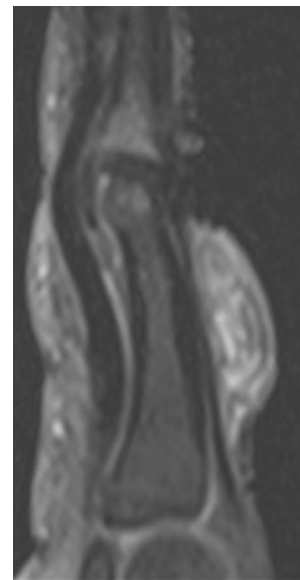
A 44-year-old man with a right index finger mass that has been present for a few years, but is now enlarging with pain (Figs. 1–4).



**Fig. 1** Axial T1- and fat-saturated FSE T2-weighted images



**Fig. 2** Axial fat-saturated T1-weighted images before and after intravenous gadolinium administration

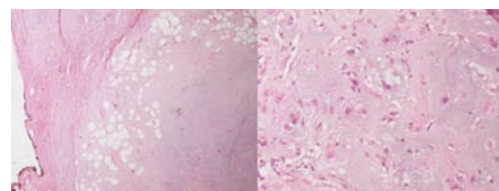


**Fig. 3** Sagittal fat-saturated T1-weighted image after intravenous gadolinium administration

The diagnosis can be found at doi:10.1007/s00256-012-1414-5.

S. Ali (✉) · W. R. Reinus  
Department of Radiology, Temple University Hospital,  
3401 North Broad Street,  
Philadelphia, PA 19140, USA  
e-mail: saychink@gmail.com

B. Leng · N. Khilko · J. S. Khurana  
Department of Pathology, Temple University Hospital,  
3401 North Broad Street,  
Philadelphia, PA 19140, USA



**Fig. 4** Low power (×25, H and E) and higher power (×200, H and E) histological images