

# Clinical-radiologic features and treatment of hepatic lesions caused by inadvertent infusion of parenteral nutrition in liver parenchyma due to malposition of umbilical vein catheters

Heidi E. Hagerott · Sakil Kulkarni · Ricardo Restrepo ·  
Jesse Reeves-Garcia

Received: 26 September 2013 / Revised: 18 December 2013 / Accepted: 22 January 2014 / Published online: 21 February 2014  
© Springer-Verlag Berlin Heidelberg 2014

## Abstract

**Background** Umbilical venous catheterization is a common procedure performed in neonatal intensive care units. Hepatic collections due to inadvertent extravasation of parenteral nutrition into the liver have been described previously in literature.

**Objective** To recognize the clinoradiologic features and treatment options of hepatic collections due to inadvertent extravasation of parenteral nutrition fluids caused by malpositioning of umbilical venous catheter (UVC) in the portal venous system.

**Materials and methods** This is a case series describing five neonates during a 6-year period at a single tertiary care referral center, with extravasation of parenteral nutrition into the liver parenchyma causing hepatic collections.

**Results** All five neonates receiving parenteral nutrition presented with abdominal distension in the second week of life. Two out of five (40%) had anemia requiring blood transfusion and 3/5 (60%) had hemodynamic instability at presentation. Ultrasound of the liver confirmed the diagnosis in all the cases. Three of the five (60%) cases underwent US-guided aspiration of the collections, one case underwent conservative management and one case required emergent laparotomy due to abdominal compartment syndrome. US used in follow-up

of these cases revealed decrease in size of the lesions and/or development of calcifications.

**Conclusion** Early recognition of this complication, prompt diagnosis with US of liver and timely treatment can lead to better outcome in newborns with hepatic collections secondary to inadvertent parenteral nutrition infusion via malposition of UVC.

**Keywords** Umbilical venous catheter · Hepatic collections · Parenteral nutrition · Ultrasound-guided drainage · Neonates

## Introduction

Umbilical venous catheterization (UVC) is a common bedside procedure in the neonatal intensive care unit (NICU). It was first described in the literature by Diamond et al. [1] in 1947 to provide venous access for exchange transfusions in newborn babies born with erythroblastosis fetalis. Umbilical venous catheters allow quick access for administering drugs, blood products, fluids and parenteral nutrition to acutely ill neonates; however, they are not without their complications. The most common complication is nosocomial sepsis ranging from 3% to 16%, followed by thromboembolism and catheter malposition in the heart, great vessels or portal system [2]. A UVC should be removed as soon as possible but can remain in place for up to 14 days [3]. We present five cases in neonates with hepatic collections due to malpositioned UVC. The newborns presented with clinical symptoms ranging from subtle abdominal distension to severe cardiorespiratory compromise. This case series emphasizes the importance of closely monitoring newborns with UVCs for development of hepatic collections, recognizing their radiologic features and understanding possible options for management of these newborns.

H. E. Hagerott (✉) · S. Kulkarni  
Department of Medical Education, Miami Children's Hospital,  
3100 SW 62nd Ave., Miami, FL 33155-3009, USA  
e-mail: heidi.hagerott@mch.com

R. Restrepo  
Department of Radiology, Miami Children's Hospital,  
Miami, FL, USA

J. Reeves-Garcia  
Department of Gastroenterology, Miami Children's Hospital,  
Miami, FL, USA

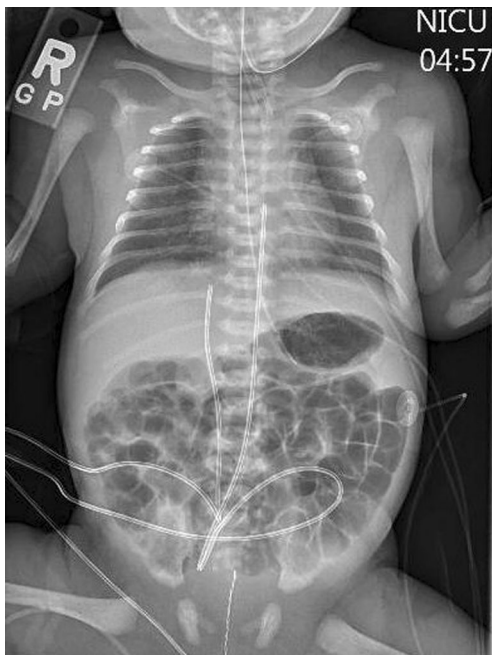## Materials and methods

The study protocol was found to be exempt by our Institutional Review Board. Over a 6-year period in a single tertiary care referral center, five neonates were identified with extravasation of parenteral nutrition into the liver parenchyma causing hepatic collections. Clinical records and imaging studies of each of the neonates were reviewed to determine presentation, imaging findings and outcome.

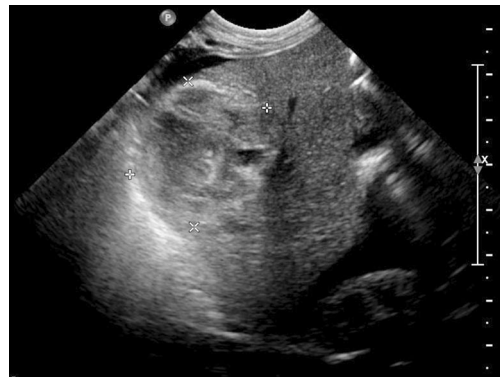## Results

### Case 1

A UVC was introduced into a newborn on day 1 of life, who was born at gestational age of 35 weeks, with a birth weight of 2.47 kg. The tip of the catheter was placed to the right of the vertebral column, at the level of T10 vertebra, below the level of the diaphragm (Fig. 1). Parenteral nutrition was initiated through the UVC. On day 7 of life, the patient developed abdominal compartment syndrome and hemodynamic instability. Laboratory findings revealed leukocytosis, thrombocytopenia and mildly elevated liver function tests. The UVC was removed and a peripherally inserted central catheter (PICC) was placed. Ultrasonography at that time revealed complex cystic mass in the liver and large amount of ascites (Fig. 2). On day 9 of life, the patient underwent emergent exploratory laparotomy, an abdominal silo was placed and a left



**Fig. 1** AP abdominal radiograph of 35-week gestational age, 2.47-kg infant on day 0 of life shows the tip of the catheter to the right of the vertebral column at the level of the T10 vertebra



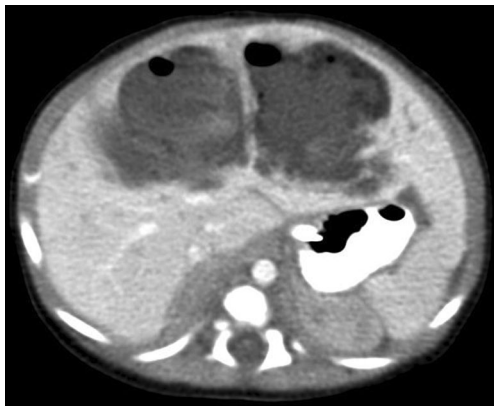**Fig. 2** Liver US of a 35-week gestational age newborn, with 2.47-kg birth weight on day 7 of life shows a complex cystic mass/collection within the liver along with a significant amount of ascites

subcapsular liver hematoma was controlled. A large amount of ascites was removed for laboratory studies, which revealed triglycerides, proteins and glucose, consistent with infusion of parenteral nutrition into the liver, rupturing the liver capsule and leaking into the peritoneum. Three days later, the surgical wound was closed by secondary intention. On day 14 of life, repeat liver function tests returned to normal. Eventually the patient was advanced to full enteral feeds without difficulties. No follow-up study has been performed since the writing of this case series.

### Case 2

On day 1 of life, a UVC was introduced in a 34-week gestational age, 3.42 kg newborn who was on a ventilator due to respiratory distress. On day 7 of life the patient was transferred to our facility because of hemodynamic instability and abdominal distension. Laboratory findings revealed leukocytosis and elevated liver enzymes.

Abdominal radiograph on day 7 of life showed that the tip of the UVC was midline, at the level of L1 vertebra, below the level of the diaphragm. It also showed a small air collection in the right upper quadrant of the abdomen. The UVC was removed immediately and a PICC was placed. A CT scan demonstrated an 8.3-cm complex air-containing fluid collection in the left and right lobe of the liver, along the falciform ligament (Fig. 3). The patient was started on antibiotics and the size of the lesion was monitored with serial liver US. The patient subsequently underwent US-guided hepatic collection aspiration because of non-response to the conservative therapy (there was no significant decrease in size). A liver US performed 4 weeks after the procedure demonstrated progressive reduction in the size of the collections in the hepatic lobes. The elevated liver function tests and leukocytosis, which were present at the time of initial presentation, resolved. At 9 months of age, a follow-up US revealed dystrophic calcifications present in the previously described areas of

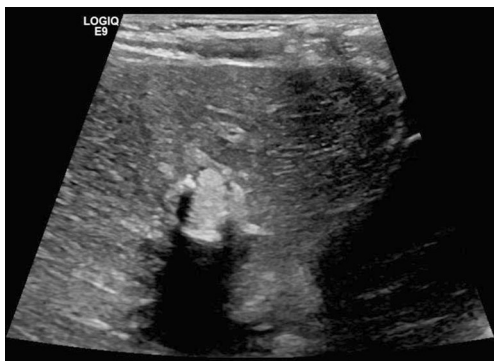

**Fig. 3** CT scan of the abdomen on day 7 of life in a 34-week gestational age, 3.42-kg newborn demonstrates a large 8.3-cm complex air-containing fluid collection in the left and right lobe

abnormal accumulation of fluid in the right and left hepatic lobes (Fig. 4).

### Case 3

A UVC was introduced into a 38-week gestational age, 4.69 kg newborn on day 1 of life. The tip of the UVC was placed to the right of the vertebral column at the level of T9, at the level of the diaphragm as confirmed by plain abdominal radiograph. The child was started on parenteral nutrition and antibiotics. On the 9th day of parenteral nutrition, the patient developed abdominal distension. Laboratory findings revealed elevated liver enzymes, in addition to abnormal coagulation factors and leukocytosis. The UVC was removed and a PICC was placed. Liver US at that time demonstrated large heterogeneous complex collection measuring  $8.9 \times 8.4 \times 5.4$  cm involving the right lobe of the liver and displacing the left lobe (Fig. 5). The newborn then underwent an US-guided hepatic collection aspiration due to the large size of the lesion (Fig. 5). Twelve days after hepatic collections aspiration, follow-up US revealed an interval decrease in the size of the complex fluid collection. The patient completed a total of



**Fig. 4** A follow-up US in a previously 34-week gestational age, 3.42-kg infant who underwent a US-guided aspiration of hepatic collection 9 months after the procedure shows a resolving lesion with residual dystrophic calcifications

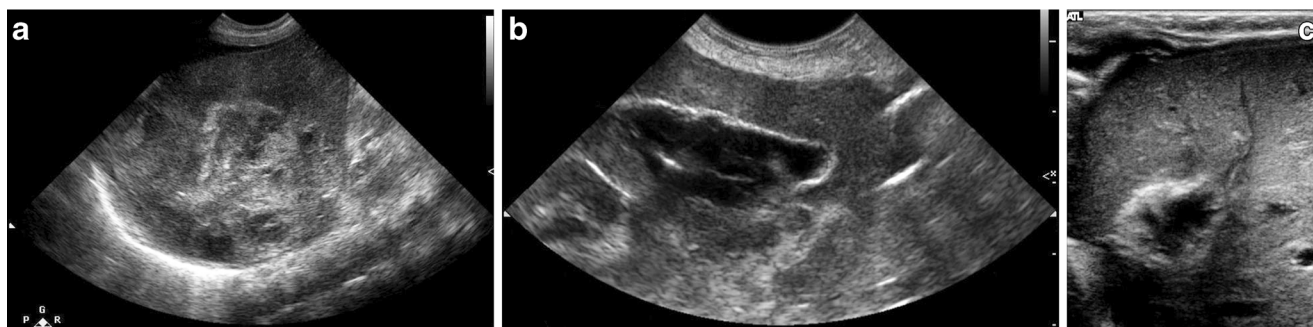
22 days of IV antibiotic treatment. Laboratory results revealed normal liver function tests, leukocyte count and inflammatory markers. A follow-up abdominal sonogram, one month later, revealed slow resolution of the complex mass in the right lobe of the liver. The echogenic margins suggested that the mass was beginning to calcify (Fig. 5).

### Case 4

A UVC was introduced into a 26-week gestational age, 1.11 kg newborn who was a ventilator due to respiratory distress. On day 2 of life the newborn was started on total parenteral nutrition. On day 7 of life the newborn developed abdominal distension and lethargy. A plain radiograph showing the position of the UVC at the time of this event is not available. The UVC was removed. A subsequent abdominal radiograph revealed normal-appearing bowel loops with central displacement, suggesting ascites. A paracentesis of the ascitic fluid resulted in the withdrawal of 84 cc of white-colored fluid, which looked like parenteral nutrition (no biochemical analysis available). The patient was stabilized and later transferred to our facility for further management. Upon transfer, a liver US was done, which revealed a thick-walled lesion with the liquid center. The child was treated with intravenous antibiotics and serial imaging. The size of the lesion progressively decreased. A CT scan, performed at 15 months for follow-up of these lesions revealed punctate calcifications along the right dome of the liver, consistent with resolving lesions due to hyper-alimentation infusion. Follow-up liver sonogram at 27 months revealed chronic unchanged small calcifications in the interlobar region.

### Case 5

On day 1 of life UVC was introduced into a newborn at gestational age of 29 weeks, birth weight of 1.22 kg. The child was intubated because of respiratory distress. Abdominal radiograph confirmed the tip of the umbilical venous catheter 2 cm to the right of the vertebral column at the level of T9, below the level of the diaphragm. Parenteral nutrition was started on day 1 of life. The patient was transferred to our facility on day 14 of life for hemodynamic instability. At our facility, the child was found to have progressively worsening abdominal distension. Laboratory findings revealed leukocytosis, thrombocytopenia and elevated liver enzymes. A liver sonogram was performed, which showed a  $5.1 \times 3.0 \times 3.4$  cm hypoechoic lesion with a hyperechoic rim replacing most of the right hepatic lobe (Fig. 6). The umbilical venous catheter was removed the following day and a central venous catheter was placed. The patient underwent US-guided aspiration of the liver lesion. A drainage catheter was subsequently placed under US guidance. The fluid was sent for biochemical analysis, which was consistent with inadvertent parenteral



**Fig. 5** US-guided drainage of a hepatic collection in a 38-week-old, 4.69-kg infant. **a** US on day 9 of life demonstrates a large heterogeneous fluid complex collection measuring 8.9×8.4×5.4 cm involving the right lobe of the liver. **b** US shows the hepatic collection during an US-guided drainage demonstrates hepatic abscess aspiration of a complex collection

in the liver. A total of 8 cc of purulent blood-tinged fluid was removed. **c** Follow-up US shows the hepatic collection after undergoing US-guided drainage. Abdominal US performed 1 month following the US-guided aspiration shows slow evolution of the 7.1-cm complex mass in the right lobe of the liver. The echogenic margins suggested early calcification

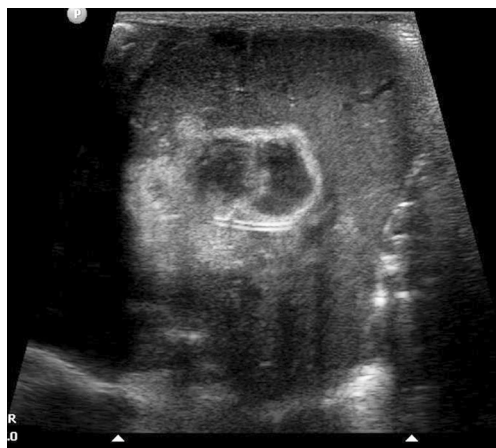nutrition infusion. A follow-up liver sonogram performed 7 days post-aspiration revealed a residual rather solid echogenic collection in the right hepatic lobe, significantly decreased in size. The drainage catheter was removed.

**Discussion**

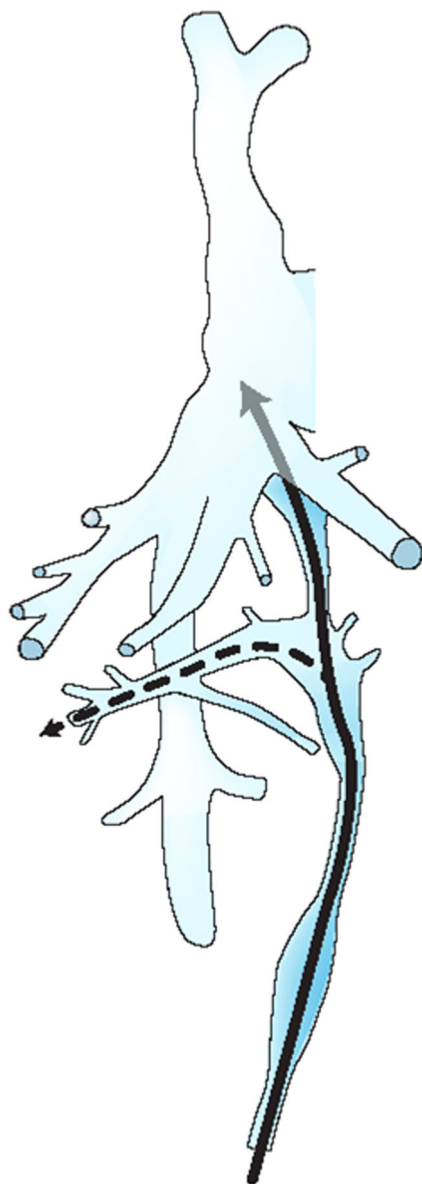
Umbilical venous catheterization is a commonly used procedure for the management of acutely ill neonates in the NICU. However, great care must be taken in assuring appropriate placement to prevent possible complications. The ideal location of the catheter tip is just below the inferior cavo-atrial junction or in the right atrium corresponding to T9 [4]. The expected course of the UVC is first through the umbilical vein, then through the medial part of the left portal vein and finally through the ductus venosus into the left hepatic vein or inferior vena cava (Fig. 7). The portal vein arises from the umbilical vein recess. Since UVC placement is a procedure performed with the help of estimations (shoulder-umbilical length)

without real-time confirmation of placement, there is a possibility that the UVC may inadvertently enter the portal venous system during placement. Also, there is a possibility of the tip migrating into the portal vein, even after initial proper placement in the ductus venosus [5]. This may lead to inadvertent infusion of hypertonic fluids such as parenteral nutrition to flow directly into the liver, causing endothelial damage and hepatic tissue necrosis [6, 7]. Hence, emphasis on placement of UVC well into the ductus venosus is imperative, although the desired location is the inferior vena cava/right atrium confluence.

The depth of insertion of the UVC can be calculated by measuring the shoulder-umbilical length and plotting it on nomograms [8]. Plain radiographs are a quick and helpful tool when determining the location of the UVC tip. However, errors often occur due to variations in bony landmarks utilized to locate the right atrium/inferior vena cava junction. A prior study used real-time US to determine the position of the tip of the UVC. They determined the most appropriate position on an AP radiograph is T8–T9. Two-thirds of the patients with the UVC tip positioned at T10 by US were shown to be in the liver. In our case series, a plain abdominal radiograph prior to onset of symptoms was available in four out of the five cases. The tip of the UVC was confirmed at level of T9 vertebra in two cases, and at T10 and L1 vertebrae in the remaining two cases. All the catheters were below the level of the diaphragm. In a prior case series of four newborns with liver collections because of malposition of UVC, all four patients had the UVC in an infra-diaphragmatic position [9]. In another case series of eight patients with parenteral nutrition ascites (four of whom had hepatic injury of US), all eight had the tip of the UVC placed below the level of the diaphragm, ranging from vertebral level T9 to T12 [10]. Prior studies have concluded that real-time US or echocardiogram are more precise techniques in determining the appropriate position of the UVC tip [4, 11]. In our case series, one of the subjects had a real-time US, which showed the position of the UVC tip at T10. A small amount of gas, which inadvertently enters the vessels during UVC placement, can be used to determine the position of the



**Fig. 6** US of the liver on day 14 of life in a 29-week gestational age 1.22-kg newborn. A 5.1×3.0×3.4-cm hypoechoic lesion with a hyperechoic rim replaces most of the right hepatic lobe. A UVC is noted crossing the collection



**Fig. 7** Incorrect course of the UVC in cases of hepatic collections. The solid line indicates the appropriate pathway of the UVC through the umbilical vein whereas the dotted line shows the UVC entering the portal venous system. (This figure has been modified from Richter and Lierse [1991]. Imaging atlas of the newborn) [13]

catheter [12]. In one of our five cases, there was a small amount of free air seen in the right upper quadrant, even though the tip of the UVC was at L1, away from this region of free air. This finding suggests that the UVC had migrated into the ductus venosus after earlier placement in the portal vein.

Abdominal distension is the most common presentation of this complication [9]. All five of our patients initially presented with abdominal distension. Two of the five patients in our case series had anemia, requiring packed red blood cell transfusion. Again, three of the five patients had hemodynamic

compromise because of this complication. In our case series, all patients developed complications in the second week of life. Our findings are similar to the prior literature, where most infants presented between days 6–10 after UVC placement [9, 10].

Ultrasound of the liver is the best modality for diagnosis and follow-up of newborns with parenteral nutrition infiltration of the liver, as demonstrated by the patients in our case series. The US finding suggestive of a parenteral nutrition infiltration of the liver is hyperechoic rimmed lesions with heterogeneously hypoechoic centers. The parenteral nutrition consists of dextrose, amino acids and lipids. Within the lesion, the parenteral nutrition infusion separates, the lipids migrate peripherally (hyperechoic) and the aqueous solution remains in the center (hypoechoic), leading to heterogeneous complex cystic appearing lesions on US [7]. During follow-up, these lesions tend to develop calcifications on US, as seen in three of the five cases in our case series. Other modalities used for diagnosis are CT and MRI of the abdomen. One of the prior studies used contrast studies of the UVC to show hepatic parenchymal staining and peritoneal extravasation in neonates with parenteral nutrition ascites [10]. One of our neonates had a CT done at initial presentation, which revealed a complex air-containing fluid collection in the liver. The authors would like to mention that even though CT scans of the abdomen were used in the above cases by the clinicians, a US of the liver is a very effective and safe modality (without radiation) in the diagnosis and follow-up of hepatic collections due to parenteral nutrition extravasation.

The treatment of these hepatic collections consists primarily of removal of the UVC, which results in rapid resolution. This was done in all five cases in our series [9]. Based on the size of the lesion, response to initial therapy and the presence of hemodynamic compromise, the further management strategies included best supportive care and serial imaging, US-guided drainage or emergent surgery. In a prior case series, best supportive care and radiologic follow-up using US was the most common treatment modality used. In our case series, in three of the five cases, US-guided drainage was successfully used as a modality of treatment. In one of these three patients, there was a failure of the initial conservative management. Hence, the child subsequently underwent a US-guided aspiration of the collections, which resulted in near resolution of the lesion on follow-up. In the other two patients, US-guided drainage was used as an initial treatment due to the presence of large complex hepatic collections, resolution of which would have taken a longer time and hence, led to a longer inpatient stay. Follow-up US imaging revealed a decrease in the size of the hepatic collections in all three cases where US-guided drainage was used. The average inpatient stay for the newborns in whom US-guided drainage was used was 41.6 days (average gestational age: 33.6 weeks), compared to 67 days (average gestational age: 30.5 weeks) in the

other cases. Apart from the lower average gestational age, the longer hospital stay in the newborns without US-guided drainage could also be due to the fact that one of the newborns developed abdominal compartment syndrome because of the hepatic collection requiring surgery. Another patient, who presented with hemodynamic instability and abdominal compartment syndrome, required an emergent laparotomy and silo placement. Just one patient in our case series was treated with only conservative medical management with follow-up imaging.

The prognosis of this condition, especially if managed appropriately, is good. None of the newborns in our case series died. Also, of those who have long-term follow-up, none has portal hypertension or chronic hepatitis. These results mirror those of a prior case series in which only one of the eight patients died of septic complications and the rest did not have any sequelae [10].

## Conclusion

Liver necrosis and collection formation are an uncommon complication of a very common procedure (UVC placement) in the NICU. Proper positioning of the tip of the catheter helps to avoid this complication. If available, real-time US should be preferred to plain abdominal radiographs to confirm proper positioning of the UVC tip. Development of abdominal distension in the second week after UVC placement must alarm the physician about the presence of this serious complication. If missed, this complication can lead to abdominal compartment syndrome and hemodynamic compromise. Ultrasound of the liver is the best initial imaging modality to confirm the clinical suspicion. Our case series shows the success of US-guided aspiration of parenteral nutrition-associated liver collections, which are large in size and fail to respond to conservative therapy. The authors believe that removal of UVC and close radiologic follow-up (using US) are mainstays of treatment of these hepatic lesions. However, one may need to resort to aggressive management strategies; US-guided

aspiration should be strongly considered in cases of large complex lesions, failure of conservative therapy and presence of hemodynamic compromise.

**Conflicts of interest** None

## References

1. Diamond LK (1947) Erythroblastosis foetalis or haemolytic disease of the newborn. *Proc R Soc Med* 40:456–550
2. Kabra NS, Kumar M, Shah SS (2005) Multiple versus single lumen catheters for newborn infants. *Cochrane Database Syst Rev* 20: CD004498
3. Sequin J, Fletcher MA, Landers S et al (1994) Umbilical venous catheterizations: audit by the Study Group for Complications of Perinatal Care. *Am J Perinatol* 11:67–70
4. Greenberg M, Movahed H, Peterson B et al (1995) Placement of umbilical venous catheters with use of bedside real-time ultrasonography. *J Pediatr* 126:633–635
5. Yigiter M, Arda IS, Hicsonmez A (2008) Hepatic laceration because of malpositioning of the umbilical vein catheter: case report and literature review. *J Pediatr Surg* 43:E39–E41
6. Lam HS, Li AM, Chu WC et al (2005) Mal-positioned umbilical venous catheter causing liver abscess in a preterm infant. *Biol Neonate* 88:54–56
7. Levkoff AH, Macpherson RI (1990) Intrahepatic encystment of umbilical vein catheter infusate. *Pediatr Radiol* 20:360–361
8. Verheij GH, Te Pas AB, Witlox RS et al (2010) Poor accuracy of methods currently used to determine umbilical catheter insertion length. *Int J Pediatr* 873167. doi:10.1155/2010/873167
9. Lin-Dunham JE, Vade A, Capitano HN et al (2007) Characteristic sonographic findings of hepatic erosion of umbilical vein catheters. *J Ultrasound Med* 26:661–666
10. Coley B, Seguin J, Cordero L et al (1998) Neonatal total parenteral nutrition ascites from liver erosion by umbilical vein catheters. *Pediatr Radiol* 28:923–927
11. Ades A, Sable C, Cummings S et al (2003) Echocardiographic evaluation of umbilical venous catheter placement. *J Perinatol* 23: 24–28
12. Oestreich AE (2010) Umbilical vein catheterization – appropriate and inappropriate placement. *Pediatr Radiol* 40:1941–1949
13. Richter E, Lierse W (1991) *Imaging atlas of the newborn*. Urban & Schwarzenberg, Baltimore