Intensive Care Med (2003) 29:1535–1540
DOI 10.1007/s00134-003-1862-4

ORIGINAL

Wolfram Schummer
Claudia Schummer
Wolf-Dirk Niesen
Hendrik Gerstenberg

Doppler-guided cannulation of internal jugular vein, subclavian vein and innominate (brachiocephalic) vein – a case-control comparison in patients with reduced and normal intracranial compliance

Received: 5 July 2002
Accepted: 16 May 2003
Published online: 24 July 2003

All work was performed at the Intensive Care Unit of the Clinic for Neurology, University Hospital Hamburg-Eppendorf, Germany.

There are no possible conflicts of interest, sources of financial support, corporate involvement, patent holdings etc. for any author.

W. Schummer (✉) · C. Schummer
Clinic for Anaesthesiology
and Intensive Care Medicine,
Friedrich-Schiller University of Jena,
Bachstrasse 18, 07745 Jena, Germany
e-mail: cwsm.schummer@gmx.de
Tel.: +49-3641-933041
Fax: +49-3641-933256

W. Schummer · W.-D. Niesen
Clinic for Neurology,
University Hospital Hamburg-Eppendorf,
Martinistrasse 52, 20246 Hamburg,
Germany

H. Gerstenberg
Clinic for Anaesthesiology,
Intensive Care Medicine and Pain Therapy,
Helios Klinikum Erfurt,
Nordhäuser Strasse 74, 99089 Erfurt,
Germany

Abstract *Objective:* A case-control comparison of Doppler guidance on the success rate of central venous cannulation in patients with normal or reduced intracranial compliance. *Design:* A single operator performed central venous access procedures with continuous wave Doppler guidance. It was used on patients on a ventilator. The position of patients with reduced intracranial compliance (RIC) was not changed for the procedure. Patients with normal intracranial compliance (NIC) were put in the Trendelenburg position. *Setting:* We prospectively evaluated 249 Doppler-guided central venous access procedures performed over a 12-month period at our 10-bed neuro-intensive care unit at a university hospital. *Patients and participants:* The group with RIC included 26 males and 35 females (n=61) aged 16–79 years. In this group 155 Doppler-guided cannulation procedures (62%) were performed. The group with NIC (n=52) comprised 29 males and 23 females aged 34–76 years; 94 Doppler-guided cannulation procedures (38%) were carried out. *Measurements and results:* The veins cannulated in RIC and NIC, respectively, were: right innominate vein: 24/18, left innominate vein 26/12, right subclavian vein 12/7, left subclavian vein 25/14, and right internal jugular vein 33/18 and left internal jugular vein 35/24. The absence of one left internal jugular vein was identified in the NIC group. The success rate of first needle pass in patients with RIC was 92% and in patients with NIC 89%. *Conclusions:* This study showed that Doppler guidance allows the cannulation of central veins in patients with RIC placed in head-up position. Cannulation can be ensured and first-pass needle placement maximised.

Keywords Catheterisation: central venous/adverse effects/methods · Observational study · Ultrasonography, Doppler · Internal jugular vein · Subclavian vein · Innominate vein · Intracranial pressure

Introduction

The indications, techniques and complications of central venous access are well documented [1, 2]. The majority of central venous access procedures are performed utilising anatomic surface landmarks alone. However, obscured or pathologically altered anatomy can make procedures more difficult. Multiple attempts and inexperienced operators have been shown to be associated with an increased risk of complications during central venous

access procedures [1, 2]. Ultrasound-guided punctures improve the success rate and minimise complication rates of central venous access procedures [3]. In this context imaging techniques represent the ideal, due to their visualisation of the vessel. However, nearly the same success rates can be obtained with conventional Doppler devices [4].

Many patients in a neurological intensive care unit suffer from reduced intracranial compliance (RIC). In these patients, a head-down position could be deleterious by increasing intracranial pressure (ICP). They are therefore often nursed in a head-up position. In this position Doppler guidance could be thought to facilitate venous cannulation, but no report has been previously published. We therefore performed this case-control comparison of Doppler guidance on the success rate of central venous cannulation of the internal jugular vein (IJV), subclavian vein (SV) and innominate (brachiocephalic) vein (IV) in patients with normal and reduced intracranial compliance.

Methods

Setting

The Neurological Intensive Care Unit (NICU) is a 10-bed ICU for neurological patients referred from hospitals in northern Germany. It provides speciality services to patients predominately suffering from specific disorders in critical care neurology (e.g. subarachnoidal haemorrhage, intraparenchymal haemorrhage, cerebral venous thrombosis, acute basilar artery occlusion, traumatic brain injury etc.) as well as acute postoperative and post-interventional management of neurosurgical/ neuroradiological patients. The clinical activity in the NICU averages 400 admissions per year with an average length of stay of 9 days.

Patients

Patients on a ventilator, admitted to our NICU during the 12-month study interval from October 2000 to September 2001 who needed central venous access for cardiovascular support or total parenteral nutrition were included in this case-control comparison of Doppler-guided central venous cannulation. Inclusion was further dependent on the operator and Doppler device being available and approval being given. Conscious patients were asked for approval, while the respective legal guardian had to approve for unconscious patients. Formal approval of a local ethics committee was not required because (a) Doppler sonography is an acknowledged method, (b) the data provides striking evidence for ultrasound-assisted cannulation and (c) vascular sonography is not associated with any known risks.

The patients were divided into two groups according to the measurements of ICP: normal intracranial compliance (NIC) and reduced intracranial compliance (RIC). Reduced intracranial compliance is found in patients with increased ICP (>20 mmHg) and with ICP that rises significantly (>5 mmHg from a baseline ICP of >15 mmHg) when the patient is put in the supine position from 10–15° head-up (see also definitions). There was no control group, patients who were not on a ventilator were excluded.

Material

The Doppler appliance used in this study was a SonoGuide2® with a SonoGuide2®—5.0 MHz probe (Ultrasound technologies, Caldicot, UK). It is suitable for an 18-gauge cannula. The ultrasound probe has to be sterilised after each usage. Unfortunately this took 2 days due to logistic problems. The SonoGuide2 is supplied complete with the following accessories: a footswitch and SonoCup disposable coupling gel, enabling a single operator to perform the procedure (Fig. 1a, b, 2).

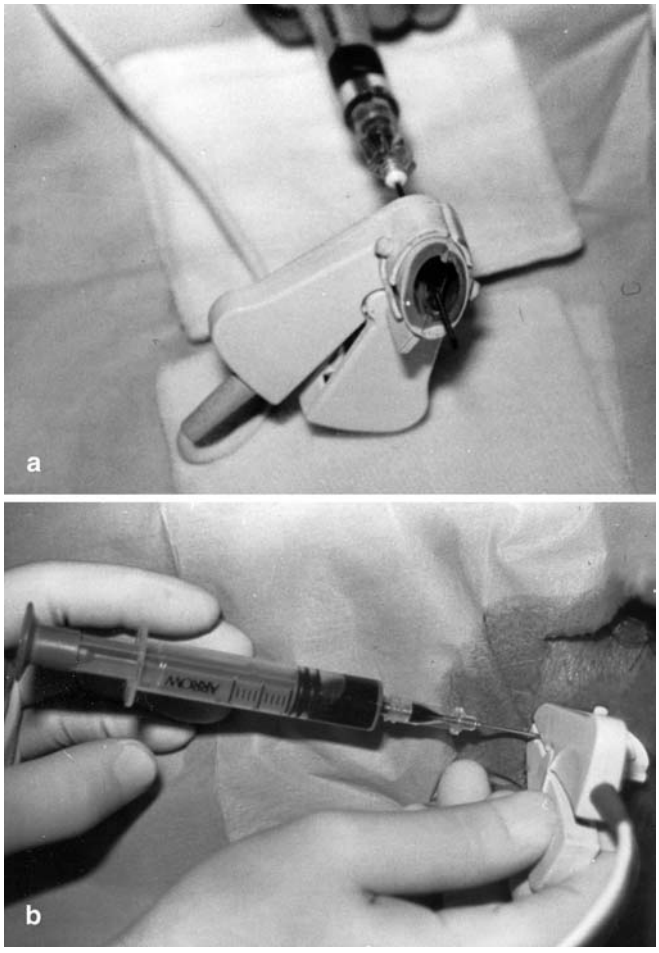

Fig. 1a, b *a* Cannula perforating SonoCup® disposable coupling gel, which is inserted in the SonoGuide2®-probe. *b* SonoCup® Doppler-probe with inserted cannula during cannulation of RIV

Documentation

In each patient information regarding age, gender, height and weight, body mass index, underlying disease, Multiple Organ Dysfunction Score (MODS) [5], the site of venipuncture, positioning during cannulation procedure and number of needle passes, and all complications, were recorded. Data were collected anonymously.

Procedure

The puncture sites were chosen by the operator according to clinical necessities. In order to minimise thrombotic risk with its detrimental consequences on cerebral venous outflow, the puncture

Fig. 2 SonoGuide2®

sites of successive cannulations were alternated. To avoid operator-linked variances, all catheterisations were performed by the same physician.

In patients with RIC, the position was not changed and the cannulation procedures were performed in head-up position (10–15° head-up). The cannulation procedures in patients with NIC could be performed in the Trendelenburg (10–15° head-down) position. In all patients the head was left in a neutral position during cannulation and intradermal 1% lidocaine provided local anaesthesia. The Doppler device was used to identify the vein and to facilitate the cannulation under sterile conditions. The probe was put on the skin at the respective landmarks. The IJVs were punctured at a mid-cervical position, the IVs behind the junction of the sternocleidomastoid muscle and medial clavicle, and the SVs at the point where they enter the thoracic inlet. Then the probe was moved and angled to receive the best Doppler signal. When the signal was clear and modulated by respiration, it was considered adequate. While the Doppler signal was continuously listened to during the venipuncture, the cannula was passed into the probe and introduced through the skin. A different typical Doppler signal could be heard when blood was aspirated. Then the guide wire was inserted through the cannula. Thereafter the procedure was identical to a standard central venous cannulation. A chest film obtained within 24 h after the procedure was evaluated for the presence of pneumothorax, haemothorax, mediastinal haematoma and malposition of the catheter.

Definitions

- Reduced intracranial compliance ($\Delta V/\Delta P$): the slope at any given point on the pressure-volume curve characterises the intracranial volume-pressure relationship. The relationship between ΔP and ΔV reflects both the viscoelastic properties, or stiffness, of the intracranial contents and the functioning of compensatory mechanisms available to reduce ICP at any given point on the curve [6]. There is no doubt that the intracranial compliance is reduced in patients with increased ICP. In patients with normal ICP, this becomes evident if the ICP rises significantly when putting the patient in a supine position from 10–15° head-up.
- One needle pass: "just one advancement of the cannula". The protocol limited the Doppler-guided needle passes to three. Thereafter a conventional puncture technique was applied without Doppler probe.
- Complications: arterial puncture, nerve injuries, pneumothorax, haematothorax, local or mediastinal haematoma, difficulties or even inability in advancing the guide wire, malpositioned catheters.
- Failures of Doppler-guided central venous cannulation: the inability to cannulate the respective vein.

Statistics

The aim of this study was a case-control comparison of Doppler-guided central vein cannulation in patients with RIC and NIC. The inhomogeneous groups and small numbers do not allow the performance of complicated statistical tests to prove that this method is the same for the two groups. To show that there is no significant difference between the success rate in the two groups, a chi-squared test was performed.

Results

We prospectively evaluated 249 Doppler-guided central venous access procedures performed over a 12-month period at our 10-bed neuro-intensive care unit at a university hospital.

Patients and participants

The group with RIC included 26 males and 35 females (n=61), aged 16–79 years. In this group 155 Doppler-guided cannulation procedures (62%) were performed. The group with NIC (n=52) comprised 29 males and 23 females aged 34–76 years; 94 Doppler guided cannulation procedures (38%) were performed. Demographic data and clinical characteristics and diagnoses on admission are shown in Table 1.

The veins cannulated in RIC were: right innominate vein (RIV): 24, left innominate vein (LIV): 26, right subclavian vein (RSV): 12, left subclavian vein (LSV): 25, and right internal jugular vein (RIJV): 33 and left internal jugular vein (LIJV): 35. The success rate of first needle pass in patients with RIC was 92%. The veins cannulated in NIC were: RIV: 18, LIV: 12, RSV: 7, LSV: 14, RIJV: 18 and LIJV: 24. The absence of one LIJV was identified. The success rate of first needle pass in patients with NIC was 89%. Procedure characteristics are shown in Table 2. Figure 3 illustrates the first needle pass success rate with respect to puncture sites in NIC and in RIC.

Doppler-guidance associated failures occurred in three cases (1.2%) (Table 2). The total failure rate of Doppler guidance in patients with NIC was 2.2% (2/93) and in patients with RIC 0.6% (1/155). No venous Doppler signal, due to absence of the respective vein, could be obtained in one case. There was a technical failure of the Doppler device in another case. The venous catheterisation was twice complicated by arterial puncture in the NIC group. Difficulties advancing the guide wire and

Table 1 Demographic data and clinical characteristics (*NIC* normal intracranial compliance, *RIC* reduced intracranial compliance, *MODS* Multiple Organ Dysfunction Score, *BMI* body mass index)

Variable	NIC	RIC
Patients (male/female)	52 (29/23)	61 (26/35)
Age (years (range))	60.6 (34–76)	53.7 (16–79)
MODS (mean (range))	7.8 (3–15)	7.3 (5–13)
BMI (kg/m^2 (range))	25.9 (17.8–55.5)	25.4 (15.5–42.5)
Catheterisations	94	155
Diagnosis on admission		
Acute subarachnoidal haemorrhage	–	16
Infarction of medial cerebral artery	2	14
Intracranial haemorrhage	9	10
Encephalitis	5	3
Severe traumatic brain injury	–	5
Acute respiratory distress syndrome	3	–
Septic shock	5	–
Acute basilar artery occlusion	5	–
Myasthenia gravis	3	–
Brain stem infarction	2	–
Guillain-Barré syndrome/ polyneuropathy	9	–
Multiple system trauma	2	–
Others	7	13

Table 2 Procedure characteristics: allocation of puncture sites and first pass success rate in patients with normal (*NIC*) and reduced (*RIC*) intracranial compliance. Failures and complications of Doppler-guided central venous cannulation according to our definitions

Puncture site	Total	Success on 1st attempt	Success after 3 attempts	Failure	Complication
RIC					
Right internal jugular vein	33	30 (91%)	33 (100%)		
Left internal jugular vein	35	32 (91%)	35 (100%)		1
Right subclavian vein	12	11 (92%)	12 (100%)		
Left subclavian vein	25	22 (88%)	25 (100%)		
Right innominate vein	24	22 (92%)	24 (100%)		1
Left innominate vein	26	25 (96%)	25 (96%)	1[a,b]	
Sum	155	142 (92%)	154 (99%)	1	2
NIC					
Right internal jugular vein	18	15 (83%)	17 (94%)	1[a]	2
Left internal jugular vein[c]	25*	23 (96%)	24 (100%)		
Right subclavian vein	7	5 (71%)	6 (86%)	1[a]	
Left subclavian vein	14	13 (93%)	14 (100%)		
Right innominate vein	18	17 (94%)	18 (100%)		1
Left innominate vein	12	10 (83%)	12(100%)		1
Sum	94*	83 (89%)*	91 (98%)*	2	4

* Thrombosis identified by Doppler, no cannulation procedure performed
[a] Conventional technique successful
[b] Technical failure
[c] Change of puncture site with successful cannulation

malpositioned central venous catheters, respectively, occurred in each group once. The complications rate in NIC was 4.3% (4/94), in RIC 1.3% (2/155).

Discussion

We examined the feasibility of Doppler guidance to facilitate central venous cannulation in patients with RIC and with NIC. As veins are easily compressible and vary in size with respiration, the Valsalva manoeuvre and head-down tilt [7], the Trendelenburg position is favoured for central venous cannulation due to venous engorgement [8, 9].

Patients with reduced intracranial compliance in the head-up position provide far from optimal cannulation conditions. The Trendelenburg position puts them at risk for ischaemic brain damage. The emphasis in the treatment of RIC is on reducing the mass of the cranial contents [10]. Therefore these patients are nursed in a head-

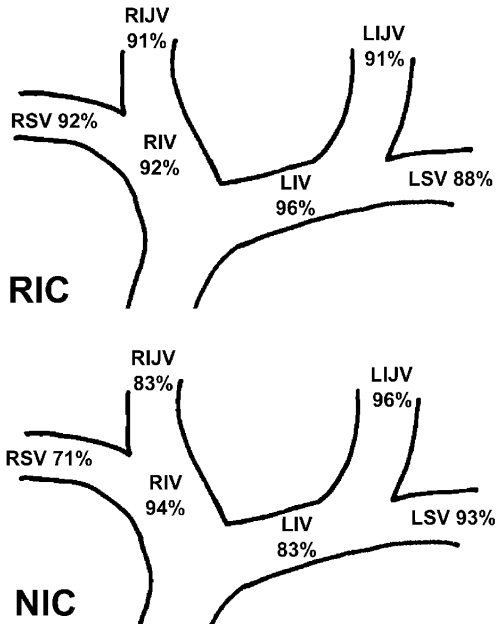

Fig. 3 First pass success rate Doppler-guided central venous cannulation with respect to puncture sites in patients with normal (*NIC*) and reduced (*RIC*) inracranial compliance. (*RIV*: right innominate vein, *LIV*: left innominate vein, *RSV*: right subclavian vein, *LSV*: left subclavian vein, *RIJV*: right internal jugular vein, *LIJV*: left internal jugular vein)

up position to prevent an increase of intracranial pressure and a decrease of cerebral perfusion pressure, respectively. These measures would be negated by the head-down position, due to the impairment of cerebral venous drainage [10]. Patients with RIC were therefore cannulated under Doppler guidance in an anti-Trendelenburg position.

The success rate of first needle pass in patients with RIC and NIC was 92% and 89%, respectively. The overall Doppler-guided success rate was 99.4% and 97.8% in patients with RIC and NIC, respectively. There was no significant difference between the two groups ($p>0.05$), which we did not anticipate. We presume that, in our setting, the effects of ventilation with positive end-expiratory pressure (PEEP) on venous blood flow might have increased the size of the veins and facilitated the cannulation procedure.

In 1984, Legler et al. published a study on Doppler-guided central venous catheterisation of IJVs [11]. Their success rate at first attempt was 77.3%. With regard to the SV, Lefrant et al. had a success rate of only 64.3% at first needle pass [12]. No literature concerning Doppler-guided cannulation of the IV exists. The IV is a rather large vessel, formed by the confluence of the IJV and SV. It is easily localised by Doppler ultrasound. In our study the first pass success rates of IV cannulation was similar to those of the other cannulation sites (Fig. 3). Due to the severity of possible complications associated with this approach, the IV has not become a popular cannulation site. However, we feel that it is a suitable vessel for Doppler-guided cannulation.

The strength of this study design is that, contrary to the studies cited above, just one operator performed all 249 catheterisations. This may be reflected in our high first pass success rate. The limitation of our study is the lack of randomisation of the venipuncture site, which was chosen according to clinical necessities. This might have caused a selection bias. Therefore we propose to repeat this study with an improved design.

With respect to failures and complications, we made the following observations: we were unable to cannulate the vein by Doppler guidance, despite a positive signal, once: this was a woman in multiple organ failure with a BMI of 55.5. Doppler conditions were very difficult. The operator decided on a conventional approach, which was successful at the second pass. A further limitation of the Doppler ultrasound is that the presence of a patent vein does not guarantee free venous passage of the guide wire or catheter. Obstruction or narrowing of the major veins is more common than generally assumed. In two cases, advancing the guide wire was accompanied by some problems, up to ultimate failure in one case.

Surface landmark-guided central venous access is a procedure with high success rates when performed under optimal circumstances and normal anatomy. By using ultrasound, Denys and Uretsky could show that only 91.5% of 200 patients had normal anatomy: 3.5% had small fixed veins, 1% had lateral alignment to the carotid artery, 2% had medial alignment to the carotid artery and in 2.5% there was a complete absence of the IJV [13]. In one patient with a large goitre displacing normal neck anatomy we also had difficulties advancing the guide wire.

Thrombosis occurs in the veins of many patients in intensive care units. Attempts to cannulate these veins will be unsuccessful, even when the anatomy is normal [14]. Failure to obtain any venous Doppler signal of the left IJV in one patient was concordant with a later diagnosis of thrombosis of this vein. We did not count this patient as a failure because the Doppler device correctly indicated the absence of the target vessel. There was one technical failure of the Doppler device, but the vein could be cannulated by conventional landmark technique at the first attempt.

Despite a positive Doppler signal, arterial puncture occurred twice. In both cases, the vein was overlying the artery. The first vein was partially thrombosed (side-diagnosis, established later by contrast-enhanced computed tomography), the second was a small and fixed vein, that did not distend during Valsalva manoeuvres or in the Trendelenburg position (both patients of the NIC group). This kind of complication may be caused by limitations of our method. If the cannula is directed through the Doppler probe, some pressure is imposed on the veins.

With needle advancement, the lumen may collapse. When the cannula pops through the anterior wall, the vessel usually re-expands. When the anterior wall is compressed against the posterior wall, the cannula will tend to perforate both walls rather than only the anterior. This mechanism may be intensified in spontaneously breathing patients and explains why blood aspiration can often be obtained only during needle withdrawal [15].

We must admit that we did not measure the cannulation time. But we can state that the set-up time of SonoGuide2 is less than 5 min. The cannulation procedure is not obviously prolonged, but detrimental effects due to altered cerebral circulation by palpation, positioning and complications are almost certainly avoided. Therefore, under elective conditions, and especially in patients with reduced intracranial compliance, any extra time is properly spent.

In conclusion, using Doppler guidance, central venous cannulation—even in the head-up position—can be ensured and first pass needle placement maximised. The latter has been shown to reduce the risk of complications [2, 3]. This may be particularly useful in the high-risk patient with reduced intracranial compliance.

References

1. Sznajder JI, Zveibil FR, Bitterman H, Weiner P, Bursztein S (1986) Central vein catheterization. Failure and complication rates by three percutaneous approaches. Arch Intern Med 146:259–261
2. Mansfield PF, Hohn DC, Fornage BD, Gregurich MA, Ota DM (1994) Complications and failures of subclavian-vein catheterization. N Engl J Med 331:1735–1738
3. Troianos CA, Jobes DR, Ellison N (1991) Ultrasound-guided cannulation of the internal jugular vein. A prospective, randomized study. Anesth Analg 72:823–826
4. Brass P, Volk O, Leben J, Schregel W (2001) [Central venous cannulation—always with ultrasound support?]. Anasthesiol Intensivmed Notfallmed Schmerzther 36:619–627
5. Marshall JC, Cook DJ, Christou NV, Bernard GR, Sprung CL, Sibbald WJ (1995) Multiple organ dysfunction score: a reliable descriptor of a complex clinical outcome. Crit Care Med 23:1638–1652
6. Artru AA (1997) CSF dynamics, cerebral edema and intracranial pressure. In: Albin MS (ed) Textbook of neuroanesthesia: with neurosurgical and neuroscience perspectives. McGraw-Hill, New York, pp 61–115
7. Hatfield A, Bodenham A (1999) Portable ultrasound for difficult central venous access. Br J Anaesth 82:822–826
8. Schreiber SJ, Lambert UK, Doepp F, Valdueza JM (2002) Effects of prolonged head-down tilt on internal jugular vein cross-sectional area. Br J Anaesth 89:769–771
9. Armstrong PJ, Sutherland R, Scott DH (1994) The effect of position and different manoeuvres on internal jugular vein diameter size. Acta Anaesthesiol Scand 38:229–231
10. Ropper AH (1993) Treatment of intracranial hypertension. In: Ropper AH (ed) Neurological and neurosurgical intensive care. Raven Press, New York, pp 29–52
11. Legler D, Nugent M (1984) Doppler localization of the internal jugular vein facilitates central venous cannulation. Anesthesiology 60:481–482
12. Lefrant JY, Cuvillon P, Benezet JF, Dauzat M, Peray P, Saissi G, de La Coussaye JE, Eledjam JJ (1998) Pulsed Doppler ultrasonography guidance for catheterization of the subclavian vein: a randomized study. Anesthesiology 88:1195–1201
13. Denys BG, Uretsky BF (1991) Anatomical variations of internal jugular vein location: impact on central venous access. Crit Care Med 19:1516–1519
14. Farrell J, Gellens M (1997) Ultrasound-guided cannulation versus the landmark-guided technique for acute haemodialysis access. Nephrol Dial Transplant 12:1234–1237
15. Mangar D, Slack KA (1993) Central venous access--a potential hazard with insertion needle! Anesth Analg 77:873