

## Case Reports/Case Series

# Case report: Managing a knotted Seldinger wire in the subclavian vein during central venous cannulation

*[Étude de cas : Extraction d'une broche guide de Seldinger nouée dans la veine sous-clavière pendant une canulation veineuse centrale]*

Kamran Z. Khan FRCA,\* Donald Graham FRCA,† Agota Ermenyi MD,† Woolagasen R. Pillay FRCS†

**Purpose:** To describe the successful removal of a knotted Seldinger wire from a subclavian vein, and review the design and structure of guidewires to formulate recommendations to minimize complications associated with the Seldinger technique.

**Clinical features:** An 81-yr-old patient suffered from an intravascular knotting of a Seldinger wire during subclavian venous cannulation. We describe a technique for successful removal of knotted guidewire under fluoroscopic guidance using the vessel dilator of a central venous cannulation kit. In this case, the technique was successful without associated immediate or delayed complications. Although central venous cannulation with the Seldinger technique is a commonly performed procedure, it may result in numerous complications, including kinking, and rarely complete knotting of the guidewire.

**Conclusions:** A thorough understanding of procedural complications and physical characteristics of the guidewire is vital in order to ensure patient safety when using the Seldinger technique for central venous cannulation. We have reviewed the relevant literature for guidewire design and structure, associated complications, and provide recommendations for safe use of guidewires.

**Objectif:** Décrire l'extraction réussie d'une broche guide de Seldinger nouée hors d'une veine sous-clavière et passer en revue la conception et la structure des broches guides afin de formuler des recommandations pour minimiser les complications associées à la technique de Seldinger.

**Éléments cliniques :** Un patient de 81 ans fut victime du nouage intravasculaire d'une broche guide de Seldinger lors d'une canulation veineuse sous-clavière. Nous décrivons une technique réussie d'extraction de la broche guide nouée sous monitoring fluoroscopique, qui se sert du dilateur de vaisseau d'un kit de canulation veineuse centrale. Dans ce cas, la technique a réussi sans engendrer de complications immédiates ou différées associées. Bien que la canulation veineuse centrale avec la technique de Seldinger soit une procédure couramment effectuée, elle peut provoquer de nombreuses complications, y compris le tordage, et plus rarement le nouage complet de la broche guide.

**Conclusion :** Une compréhension exhaustive des complications procédurales et des caractéristiques physiques de la broche guide est essentielle afin d'assurer la sécurité des patients lors de l'utilisation de la technique de Seldinger pour la canulation veineuse centrale. Nous avons passé en revue la littérature pertinente au sujet de la conception et de la structure de la broche guide, des complications associées, et fournissons des recommandations pour un usage sécuritaire des broches guides.

CAN J ANESTH 2007 / 54: 5 / pp 375-379

From the Nuffield Department of Anesthetics,\* University of Oxford, John Radcliffe Hospital, Oxford; and the Royal Infirmary,† Doncaster, United Kingdom.

*Address correspondence to:* Dr. Kamran Z. Khan, Nuffield Department of Anesthetics, University of Oxford, John Radcliffe Hospital, Headington, Oxford, OX3 9DU, UK Phone: +44 1865 851136; Fax: +44 1865 220027; E-mail: kamran.khan@nda.ox.ac.uk  
There was no funding for this report and the authors have no conflicts of interest with the manufacturers of the medical devices described in this report.

*Accepted for publication January 12, 2007.  
Revision accepted February 19, 2007.*

**T**HE Seldinger technique is the standard approach to central venous cannulation, though it is associated with numerous well-known complications. Mechanical complications of central venous cannulation occur in 5 to 19% of patients.<sup>1,2</sup> Guidewire-associated complications include: failure to pass, loss in the vessel, kinking, and breakage. Among rare complications there have been case reports of extravascular<sup>3</sup> and intravascular<sup>4,5</sup> looping and knotting of the guidewires. Safe use of guidewires for central venous access requires care in handling and understanding of their physical characteristics including tensile strength and structure. We present a case of intravascular knotting of a J-tipped guidewire and its successful removal under fluoroscopic guidance. This is followed by a review of design and structure of guidewires, reported complications, and recommendations for use. The patient granted consent for publication of this report according to the local Ethics Committee guidelines.

### Case report

An 81-yr-old male was admitted for total gastrectomy. His past medical history included hypertension and acid peptic disease for which he was taking nifedipine and lansoprazole. He was slightly claustrophobic and had a history of easy fainting. Recently, he had been diagnosed with adenocarcinoma of the stomach, which was confirmed on biopsy. One month after his staging laparoscopy he was admitted for tumour resection.

On the day of admission his blood pressure was 145/81 mmHg with a pulse rate of 76 beats·min<sup>-1</sup>. He was 175 cm tall and had a body mass index of 32 kg·m<sup>-2</sup>. He underwent total gastrectomy under general anesthesia, which was uneventful. A feeding jejunostomy tube was sited intraoperatively. The patient made a good immediate postoperative recovery without significant problems.

Later he developed severe postoperative ileus. On the ninth postoperative day a computed tomography scan showed dilated intestine with no other significant findings. It was decided that he should have central venous access to facilitate total parenteral nutrition. He was referred to the anesthetic team for insertion of a central venous catheter prior to discharge from the high dependency unit (HDU).

Verbal consent for central venous cannulation via the subclavian approach was obtained. Standard barrier protection was maintained, and 7 mL of 1% lidocaine was injected to the entry site in the right infraclavicular area. In line with standard practice, a Seldinger wire technique was used to site a 7 Fr triple

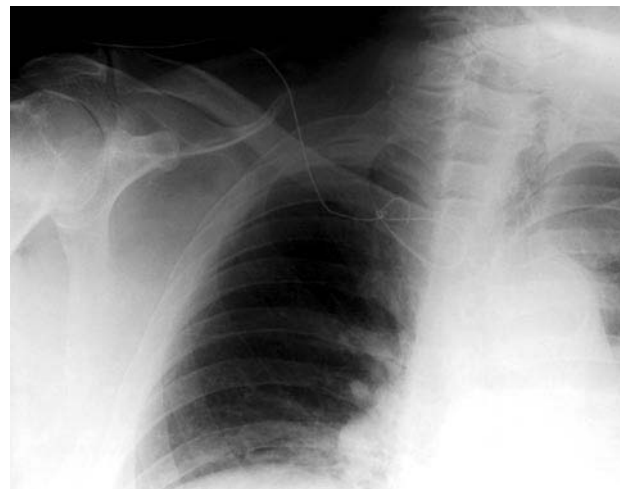


FIGURE 1 Chest radiograph of the patient showing a knotted guidewire in the subclavian vein.

lumen catheter. The subclavian vein was identified on the first attempt without complications. However, threading the 0.81 mm J-tip guidewire through the 18 G needle proved difficult. Needle and wire were removed from the insertion site en bloc. At the second attempt using the same insertion site, the vein was re-identified uneventfully. This time the Seldinger wire was passed through the needle, though a slight resistance was noted. After removal of the needle, the dilator was threaded over the wire. On removal of the dilator the wire was found to be kinked, so it was decided to remove the wire. The wire was initially withdrawn easily, but at approximately 7 cm remaining *in situ* further removal was not possible despite firm tension. Consultant help was sought and the tract was dissected under local anesthesia, however any further attempts at removal were unsuccessful. General surgical advice was sought while a chest *x-ray* was performed, which showed the guidewire to be looped and knotted in the periclavicular area (Figure 1).

Following discussion with the consultant vascular surgeon, a decision was made to remove the wire under sedation and fluoroscopic guidance in the operating room. After explaining the situation to the patient and obtaining informed consent, he was transferred to the emergency operating room. A combination of ketamine and midazolam was used for conscious sedation under routine monitoring. With fluoroscopic control, the vascular surgeon used the central venous line dilator to straighten the wire and remove it. Considerable force was required to remove the wire and as a consequence, the proximal end of the wire broke, but

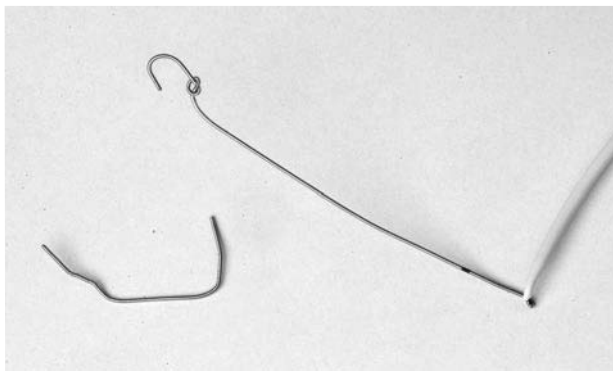


FIGURE 2 Knotted guidewire after removal with the vessel dilator. The broken proximal part of the guidewire is also shown.

eventually the circumference of the knot was reduced allowing the knotted wire to be removed (Figure 2). Following removal of the wire a left subclavian venous catheter was inserted uneventfully.

A postoperative chest *x-ray* taken in the postanesthesia care unit, and a follow-up film six hours later in the HDU revealed no signs of hemothorax or pneumothorax. The patient was discharged from the HDU to the ward the next day without further complications.

### Discussion

Safe use and handling of guidewires for central venous cannulation requires an understanding of the structure and physical characteristics of the wires. Monaca *et al.*<sup>6</sup> have recently described the structure of a commonly used guidewire. According to their detailed description the guidewire consists of an inner single filament wire core and a surrounding coiled wire-cover. The latter is designed as a helix of stainless steel to form a tunnel for the inner wire and provides elastic properties. Apart from the two ends of the guidewire where the outer spiral is welded to the inner wire, there is no further point of attachment between the core and the outer wire. The typical J-shaped curvature is achieved by flattening the round core to a thickness of 0.1 mm wire at approximately 2.5 cm from the tip. This structure provides increased flexibility at the J-shaped tip. However it becomes an area of structural weakness at the junction of the rounded and flattened segments, which can lead to potential breakage.

The length and diameter of these wires are variable to meet specific needs. In older versions many spring

guidewires also incorporated a smaller straight wire (safety wire) running parallel to the inner core (mandrel), which was attached to both ends of the coil. This smaller core wire was employed to reduce the possibility of kinking or stretching the coil with resultant fracture. In addition, it prevented fragment migration or embolization if coil separation occurred.<sup>7</sup>

The specific design of these wires is a 'patent' of each manufacturer. Edwards Life Sciences have informed us that their guidewires comply with ISO 11070:1998 standards (personal communication). However the part of the standard<sup>A</sup> relevant to coated guidewires states:

*"The guide wire to be coiled several times around a cylinder whose radius is scaled to the diameter of the guide wire"*.

The guidewire then is examined visually for the presence of cracks, splits, and dehiscence.<sup>8</sup>

However, compliance with these standards in North America does not imply that the guidewire meets FDA standards.<sup>9</sup> The stability of the guidewire is routinely examined at certain tension loads. Monaca *et al.*<sup>6</sup> have described some other details of guidewire manufacturing and testing. According to these, the weld seams between the inner core and the outer covering at both ends are supposed to withstand tension of at least 17 N (1.73 kg force) before they detach, whereas in its middle section, the complete guidewire should withstand a stress of approximately 290 N (29.57 kg force).

The outer material, 'the coil', of the guidewire is usually made of stainless steel and the inner material is made of 'nitinol', which is an alloy of nickel and titanium (personal communication, B. Braun). Recently, a new type of guidewire has been developed at Tohoku University in Japan, which is a *Cu-Al-Mn* (copper, aluminium and manganese) alloy. This has graded characteristics with super elasticity at the tip as well as high stiffness in the middle part. This allows greater tension and rotational stress to be applied.<sup>10</sup> This new guidewire is not yet available in commercial central venous catheter kits.

The Seldinger technique is not devoid of complications attributable purely to the employment of guidewires. Extravascular<sup>3,11</sup> and intravascular<sup>4-6</sup> looping and knotting are well-reported complications. Shearing<sup>12</sup> and fracture, or impaction of the wires have also been reported. Similarly, paradoxical embolization of a fractured guidewire<sup>13</sup> is a known

A ISO. Sterile, single-use intravascular catheter introducers. Geneva, Switzerland. International Organization for Standardization. ISO 11070:1998.

complication. These complications are related to damage or mechanical disruption of the normal structure of the wire.

However, occasionally even the insertion of an entirely intact guidewire can cause problems. Excess introduction of the wire may result in cardiac arrhythmias.<sup>14</sup> In one case, excessive introduction of a guidewire caused a cyst arising from the tricuspid valve annulus to prolapse into the right ventricular outflow tract and cause cardiac arrest with electromechanical dissociation.<sup>15</sup> Contamination<sup>16</sup> of the guidewire during insertion has been reported in the literature as well as misplacement and loss of guidewires in the cardiovascular system.<sup>17</sup> Special precautions are required in patients with inferior vena cava filters since there have been numerous reports of entrapment of guidewire in these filters.<sup>18,19</sup> There have been rare cases of fatal pericardial tamponade<sup>20,21</sup> following guidewire insertion.

Intravascular and extravascular looping and knotting and any further damage to the structure of the guidewires can be prevented if caution is used during their handling. Guidewires are not very rigid structures and if any force is applied they are likely to kink or loop. Further application of force after looping might result in knot formation. There are two elements in the sequence of the Seldinger technique that are potentially important in preventing the kinking of the wire. First, during insertion of the wire through the needle no resistance should be encountered, and the wire should pass freely, without any force into the vein. To avoid shearing, the wire should not be pulled back through the needle once it has passed the bevel. Second, care should be exercised when passing the dilator over the wire. Forcing the dilator in a direction that diverges from the path of the wire can result in kinking the wire and potentially cutting out through the vein with possibly fatal consequences.<sup>22</sup>

Knotting of the wires is almost exclusively described in the literature following the subclavian approach, although it has also been described once during attempted femoral vein cannulation.<sup>23</sup> This could be due to the fact that the path of the subclavian vein is not straight, as it loops over the first rib to descend into the superior mediastinum. Further to this, there is a pinch area between the clavicle and the first rib, which can impede the anterograde threading of the wire and might contribute to looping and knotting.

The axillary vein approach is an alternative to the subclavian approach. Attractions of this technique include the ease with which the axillary vein can be visualized using ultrasound.<sup>24</sup> This technique is described as having a low complication rate although

it is uncertain whether the incidence of guidewire complications *per se* is lower when cannulation is ultrasound-guided.<sup>25</sup> We suggest that the following precautions may reduce the risk of complications. First, special care should be taken in known cases of altered anatomy or where previous cannulation has occurred at the same site. On encountering any resistance the guidewires should not be advanced. The guidewire and needle should be withdrawn as an assembly to prevent the cutting and shearing of the wire by the sharp needle tip. After more than one attempt, the integrity of the wire should be rechecked. A sufficiently large skin incision should be used in order to thread the dilator and the line over the wire smoothly to prevent kinking of the wire at the skin. One end of the guidewire should always be held by the operator at all times to minimize the risk of loss in the blood vessel. Some manufacturers allow use of the straight end of the wire on insertion; but in general this is not recommended.<sup>B</sup> If the wire is fixed, force should not be applied to remove it. This might result in separation of the coil and the core resulting in fracture of the wire. Finally, if minimal to moderate force needs to be applied then forceps should be used to grasp the wire in a way that the outer coil and the inner core are grasped together and separation does not occur.

In conclusion, although it is not possible to study the optimal method of removal of a knotted guidewire, there are case reports suggesting that this should be done under fluoroscopic guidance. A vessel dilator can be used to tighten the knot into its smallest circumference, allowing it to be withdrawn along with the dilator. Closure of the vessel in a controlled fashion, for example by a purse-string suture,<sup>26</sup> may limit the risk of hemorrhage and air embolism, and is best performed by a vascular surgeon in the operating room, as in our case. We suggest that this approach should be followed, as removal of a looped or knotted wire may cause vessel damage, major hemorrhage and the need for urgent surgical intervention. Adhering to the recommended precautions will reduce the risk of mechanical complications associated with the Seldinger technique.

B B. Braun. Manufacturer's instructions for use. Central venous catheter for Infusion therapy. Melsungen AG, Melsungen, Germany: February 2002.

## References

- 1 Merrer J, De Jonghe B, Golliot F, et al; French Catheter Study Group in Intensive Care. Complications of femoral and subclavian venous catheterization in critically ill patients: a randomized controlled trial. *JAMA* 2001; 286: 700-7.



- 2 *Mansfield PF, Hohn DC, Fornage BD, Gregurich MA, Ota DM.* Complications and failures of subclavian-vein catheterization. *N Engl J Med* 1994; 331: 1735–8.
- 3 *Wang LP, Einarsson E.* A complication of subclavian vein catheterisation. Extravascular knotting of a guide-wire. *Acta Anaesthesiol Scand* 1987; 31: 187–8.
- 4 *Carpentier JP, Braz da Silva J, Choukroun G.* Formation of a knot in a J spiral metallic guide: a complication of the Seldinger method (French). *Cah Anesthesiol* 1991; 39: 277–8.
- 5 *Koundouris C, Tornaris G, Charopoulos I, Vounasis A, Solomou G.* Subclavian vein flexible guidewire knotting. A potential serious complication in hemodialysis patients. *Chirurgia (Bucur)* 2004; 99: 61–4.
- 6 *Monaca E, Trojan S, Lynch J, Doehn M, Wappler F.* Broken guide wire - a fault of design? *Can J Anesth* 2005; 52: 801–4.
- 7 *Schwartz AJ, Horrow JC, Jobs DR, Ellison N.* Guide wires--a caution. *Crit Care Med* 1981; 9: 347–8.
- 8 *Triolo P.* Using risk analysis to develop coated medical devices. Available from URL; <http://www.device-link.com/mddi/archive/05/01/006.html> (accessed 28/05/06) 2005.
- 9 *U.S. Food and Drug Administration.* Recognition and use of consensus standards; final guidance for industry and FDA staff, (Rockville, MD: FDA:); Available from URL; <http://www.fda.gov/cdrh/ost/guidance/321.html> (accessed 28/05/06) CDRH, June 2001.
- 10 *Sutou Y, Omori T, Furukawa A, et al.* Development of medical guide wire of Cu-Al-Mn-base superelastic alloy with functionally graded characteristics. *J Biomed Mater Res B Appl Biomater* 2004; 69: 64–9.
- 11 *Hoogsteden L, Filshie J, Querci della Rovere G.* Knotted guidewire – A complication of Hickman line insertion. *Anaesthesia* 1996; 51: 713.
- 12 *Chhabra B, Kiran S, Sekhri C.* Shearing of guide wire: a complication of central venous catheterization. *Journal of Anaesthesiology* 2002; 18: 99–101.
- 13 *Cassery IP, Goldstein JA, Rogers JH, Lasala JM.* Paradoxical embolization of a fractured guidewire: successful retrieval from left atrium using a snare device. *Catheter Cardiovasc Interv* 2002; 57: 34–8.
- 14 *Lee TY, Sung CS, Chu YC, Liou JT, Lui PW.* Incidence and risk factors of guidewire-induced arrhythmia during internal jugular venous catheterization: comparison of marked and plain J-wires. *J Clin Anesth* 1996; 8: 348–51.
- 15 *Quiney NF.* Sudden death after central venous cannulation. *Can J Anaesth* 1994; 41: 513–5.
- 16 *Palmer S, Solano T.* Contamination of guidewires during insertion of central venous catheters in an intensive care setting. *Infect Control Hosp Epidemiol* 2005; 26: 506–7.
- 17 *Lum TE, Fairbanks RJ, Pennington EC, Zwemer FL.* Profiles in patient safety: misplaced femoral line guide-wire and multiple failures to detect the foreign body on chest radiography. *Acad Emerg Med* 2005; 12: 658–62.
- 18 *Duong MH, Jensen WA, Kirsch CM, Wehner JH, Kagawa FT.* An unusual complication during central venous catheter placement. *J Clin Anesth* 2001; 13: 131–2.
- 19 *Liddell RP, Spinosa DJ, Matsumoto AH, Angle JE, Hagspiel KD.* Guidewire entrapment in a Greenfield IVC filter: ‘rail and reins technique’. *Clin Radiol* 2000; 55: 878–81.
- 20 *Cavatorta F, Campisi S, Fiorini F.* Fatal pericardial tamponade by a guide wire during jugular catheter insertion. *Nephron* 1998; 79: 352.
- 21 *Booth SA, Norton B, Mulvey DA.* Central venous catheterization and fatal cardiac tamponade. *Br J Anaesth* 2001; 87: 298–302.
- 22 *Jankovic Z, Boon A, Prasad R.* Fatal haemothorax following large-bore percutaneous cannulation before liver transplantation. *Br J Anaesth* 2005; 95: 472–6.
- 23 *Wong CS, Wong KL, Sit KE, Chen CC, Sia SL, Wei TT.* Guide wire knotting in the femoral vein during central venous catheterization (Chinese). *Ma Zui Xue Za Zhi* 1992; 30: 55–7.
- 24 *Galloway S, Bodenham A.* Ultrasound imaging of the axillary vein--anatomical basis for central venous access. *Br J Anaesth* 2003; 90: 589–95.
- 25 *Sharma A, Bodenham AR, Mallick A.* Ultrasound-guided infraclavicular axillary vein cannulation for central venous access. *Br J Anaesth* 2004; 93: 188–92.
- 26 *Pachai A.* Guidewire knot formation during insertion of a central venous catheter (Danish). *Ugeskr Laeger* 1997; 159: 5534–5.