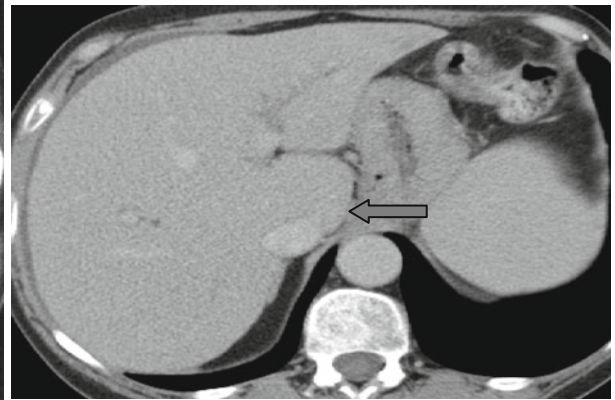
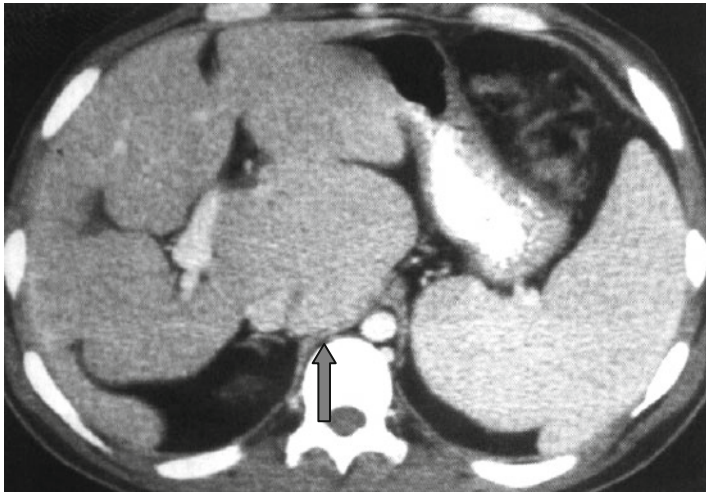
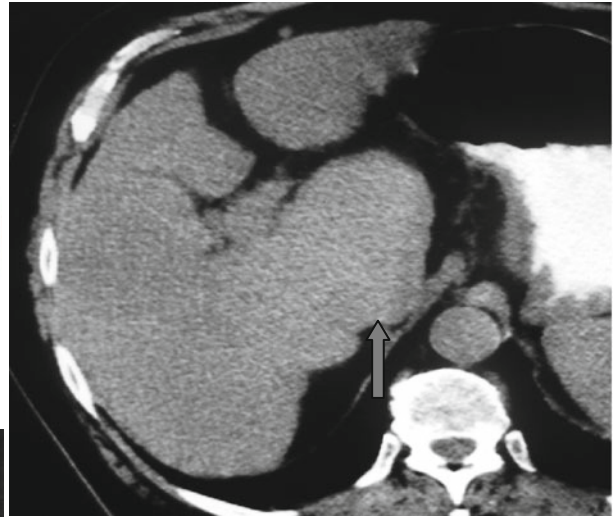


## Boxing Glove Sign



The first liver segment (caudate lobe) that increased in size may be the first and only sign of liver cirrhosis on CT. Covering three borders of the inferior vena cava, the first

segment of the liver creates a view of a boxing glove in form – the “*boxing glove*” sign (↑). This sign can be combined with other implications of cirrhosis.