

Case Study 22

Choroidal Melanoma

JC is a 60-year-old man who presented to his ophthalmologist with the complaint of recently decreased vision in his right eye. Examination with the ophthalmoscope showed a swollen optic nerve head with some engorgement of the retinal vessels consistent with a central retinal vein occlusion. Echography was performed, and the optic nerve was found to be thickened on A-scan examination with a moderate degree of fluid within the nerve sheath (Fig. 1). The examiner approached the patient systematically and scanned the opposite eye and incidentally found a peripheral choroidal tumor that was highly consistent with a malignant melanoma (Fig. 2).

An accurate differential diagnosis of a pathological process can sometimes be influenced by proper localization.

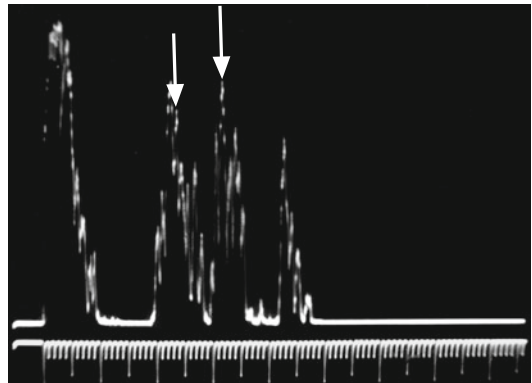


FIG. 1 Thickened optic nerve (*vertical arrows at nerve sheaths*)

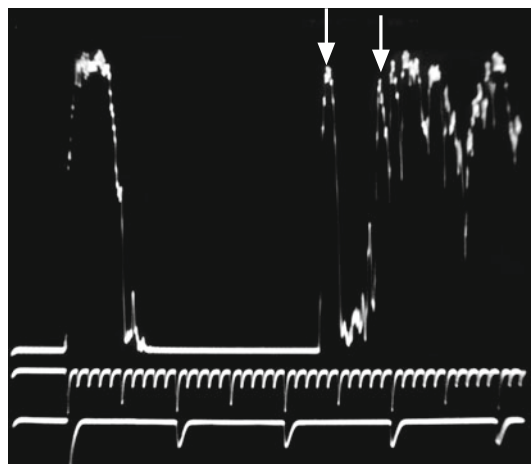


FIG. 2 A-scan of choroidal melanoma (*first vertical arrow at tumor surface and second vertical arrow at sclera*)

This chapter contains video segments that can be found by accessing the following link: <http://www.springerimages.com/videos/978-1-4614-7081-6>.