

Bilateral Acute Angle-Closure Glaucoma Following Treatment with Topiramate for Headache

Chanda Kulkarni · Urmimala Ray Chaudhuri · Annalakshmi Jagathesan

To view enhanced content go to www.neurologytherapy-open.com

Received: December 6, 2012 / Published online: March 26, 2013

© The Author(s) 2013. This article is published with open access at Springerlink.com

ABSTRACT

Introduction: This case report adds supportive evidence to the development of acute angle-closure glaucoma (AACG), a rare but serious adverse effect following the use of topiramate (TPM) for a severe headache.

Case Report: A 25-year-old female reported with severe headache, suspected to be migraine, and was started on TPM 25 mg/day on the first day. However, she presented at the emergency clinic of a hospital with sudden blurring of vision and colored halos 5 days after stopping the drug, i.e., day 8. She was subjected to ophthalmic examination and was diagnosed with AACG. The intraocular pressure (IOP) was found to be elevated and she was hence started on acetazolamide 500 mg instantly, maintained on tablet acetazolamide 250 mg four times a day (QID), pilocarpine 2% eye drops QID, travoprost 0.004% once a day (OD), and dorzolamide 2% eye drops three times a day (TID). After a week's treatment, there was rapid improvement with return of IOP to normal.

Conclusion: TPM-induced AACG is a rare serious adverse event leading to blindness but is preventable, when diagnosed early and by instituting appropriate treatment.

Keywords: Acute angle-closure glaucoma; Headache; Intraocular pressure; Neurology; Ophthalmology; Topiramate

Enhanced material for this paper is available at <http://www.neurologytherapy-open.com>.

C. Kulkarni (✉) · A. Jagathesan
Division of Clinical Pharmacology, St. John's
Medical College, Bangalore, India
e-mail: drchandakulkarni@gmail.com

U. R. Chaudhuri
Dayananda Sagar College of Dental Sciences,
Kumaraswamy Layout, Bangalore, Karnataka, India

Present Address:
U. R. Chaudhuri
University of North Texas Health Science Center,
3500 Camp Bowie Blvd, Fort Worth, TX, USA



Enhanced content for this article is
available on the journal web site:
www.neurologytherapy-open.com

INTRODUCTION

Migraine is typically characterized by a pulsating headache with or without aura, nausea, and vomiting. The drugs commonly used in acute migraine attacks are sumatriptan (which is one of the triptans chemically grouped under serotonin agonists) and ergot alkaloids, while propranolol and calcium channel blockers are used prophylactically. However, recently topiramate (TPM), an anti-epileptic drug, has gained popularity as a first line drug for use in prophylaxis of migraine [1].

The use of TPM for epilepsy and migraine has been approved by the US Food and Drug Administration (FDA) and it also has a number of “off-label” indications, such as bulimia nervosa, alcohol dependence, smoking, and possibly a depressive phase in bipolar disorders [2].

The most significant adverse effects associated with TPM include psychomotor slowing, difficulty in concentration, somnolence, and fatigue. Additional non-specific central nervous system (CNS) adverse effects are dizziness, confusion, and memory problems. The dose and duration-dependent use include renal stones, weight loss, and paresthesia [3]. Recently, evidence has been accumulating on a rare but serious adverse event on TPM-induced acute myopia with acute angle-closure glaucoma (AACG) both as spontaneous case reports and case series [4–7]. A “black box” warning was, therefore, issued by the FDA in 2004, regarding its potential to induce AACG as a precaution for practicing physicians [8].

The World Health Organization (WHO) has estimated that India has a 1% prevalence of blindness. Of the estimated 8.9 million blind in India, 12.8% are due to glaucoma [9]. While there is population-based data available on

primary glaucoma from South Asia, especially India, data on secondary drug-induced glaucoma are lacking, except for spontaneous reports [10]. The authors report an observation of a case, where a female patient developed AACG after 8 days, following TPM 25 mg/day, once a day (OD), for 3 days as an adverse reaction to TPM.

CASE REPORT

A 25-year-old female presented with severe headache and was diagnosed with migraine. She was started on TPM 25 mg/day; however, she stopped the treatment after 3 days without consultation as her headache was not relieved. After 5 days of stopping the treatment with TPM, she presented at the emergency clinic of a hospital with complaints of blurred vision and severe pain in both the eyes, which were of a few hours in duration. She also complained of colored halos and headache associated with nausea with no family history of eye-related disorders. On ophthalmic examination, the visual acuity was found to be 3/60 in both the eyes, and did not show improvement in visual acuity in the pinhole test. There was bilateral lid edema, ciliary congestion, and chemosis. Both anterior chambers were found to be shallow, appeared occluded in the periphery, and pupils were reactive. Applanation tonometry revealed high intraocular pressure (IOP) of 34 and 32 mmHg, in the right and left eyes, respectively (Fig. 1).

A diagnosis of AACG, precipitated following oral administration of TPM, was made. While, laser peripheral iridotomy would have been an ideal procedure for AACG, due to presence of choroidal effusion along with anterior migration of anterior structures this treatment option was not considered in this case. She was hence started on acetazolamide tablets 250 mg

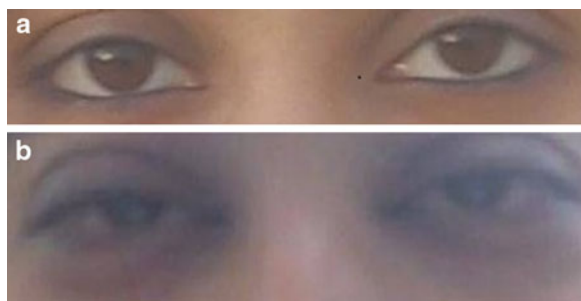


Fig. 1 A photograph of normal (a) and glaucomatous (b) eyes

four times a day (QID), pilocarpine 2% eye drops QID, travoprost 0.004% OD, and dorzolamide 2% eye drops three times a day (TID). Since she had already stopped TPM, she was advised not to take it again and was reviewed the next day. The repeat ophthalmic examination on the second day showed improved vision (6/60) in both the eyes, reduction in conjunctival chemosis, and improved depth of anterior chamber, while it continued to be shallow peripherally. IOP measurements were repeated using applanation tonometry and were found to be 20 and 18 mmHg, in the right and left eyes, respectively. On the third day, her vision improved to 6/12 in the right eye and 6/6 partial (p) in the left with IOP 10 and 14 mmHg, respectively. The ophthalmoscopic examination of disc and macula was normal in both the eyes. Subsequent examination on the fifth day showed improved visual acuity 6/6 p in both the eyes and IOP was 14 and 12 mmHg and the anterior chamber appeared well formed.

She was advised to taper the anti-glaucoma medication and was examined a month later when her visual acuity was 6/6, with IOP 14 mmHg in both the eyes and was then advised via evaluation by a glaucoma specialist.

All procedures followed were in accordance with the ethical standards of the responsible

committee on human experimentation (institutional and national) and with the Helsinki Declaration of 1975, as revised in 2008. Written informed consent was obtained from the patient for which identifying information is included in this case report.

DISCUSSION

There have been 115 case reports of ocular side effects, 86 cases of secondary angle-closure glaucoma, and 7 cases of permanent visual loss reported with TPM, suggesting an association between acute onset of AACG after TPM therapy [11, 12]. The present case report adds evidence to show symptoms of acute onset of blurred vision associated with ocular pain to be due to adverse event associated with TPM prescribed for migraine. The ciliary body edema, uveal effusion, and relaxation of zonules along with anterior rotation of the ciliary body resulting in forward shift of the iris-lens apparatus are reported to contribute to TPM-induced AACG. In addition, these latter effects are said to produce shallow anterior chamber, leading to an increase in IOP and thus precipitating the acute glaucomatous attack secondary to the increase in IOP.

TPM primarily introduced for the treatment of epilepsy is said to act by modulation of the voltage gated sodium channels, strengthening gamma-aminobutyric acid (GABA)ergic activity and reduction in the effects of activation of glutamatergic receptor of alpha-amino-3-hydroxy-5-methyl-4-isoxazolepropionic acid (AMPA)-kainate subtype. Interestingly, TPM is also known to share weak carbonic anhydrase (CA)-inhibitor activity like acetazolamide, hence paradoxically, is an effective anti-glaucoma drug. However, as a CA inhibitor it is linked with the occasional development of renal calculi and also being a sulfa-based drug

by itself is reported to induce AACG through an idiosyncratic reaction [13, 14].

The potential to cause glaucoma may, therefore, be attributed to a mechanism independent of the well-known pharmacodynamic effects involved in anti-convulsant activity of TPM. Several studies do report on the genetic basis of primary open-angle glaucoma (POAG) and juvenile onset open-angle glaucoma (JOAG) [15, 16]. The genetic predisposition may also be considered as a cause for AACG in some individuals, although several reports propose on usage of TPM to induce secondary AACG [4, 5, 17, 18].

It is to be noted that ideally patients presenting with increased IOP will be subjected to ophthalmic examination like gonioscopic examination with ultrasound biomicroscopy which are recommended routinely [5, 18]. However, these were not carried out in this particular patient, which may be due to the fact that the presenting history clearly revealed a diagnosis of TPM-induced AACG. Thus, the presenting nature of the symptoms has possibly warranted initiation of anti-glaucoma therapy immediately. The other tests for glaucoma work-up like Glaucoma diagnosis-Variable Cornea Compensation (GDx-VCC) and Optical Coherence Tomography (OCT), which are both expensive and not mandatory in the acute phase of AACG, were not carried out.

It is to be noted that ideally the present case could have been subjected to complete ophthalmic examination to include gonioscopic examination along with ultrasound biomicroscopy and iris configuration as recommended routinely [5, 18]. The diagnosis in this case was primarily based on detailed history taking as these tests are not carried out routinely due to economic constraints in the Indian context.

While TPM was discontinued, this patient was prescribed miotics like pilocarpine as eye drops, which is reported to be of doubtful benefit in the treatment of TPM-induced glaucoma along with sulfa drugs like acetazolamide and dorzolamide. It is hence important to note that administration of these medications appears inappropriate as these are likely to exacerbate the condition and could have been avoided. In addition, the treatment regimen did not include anti-inflammatory medication such as prednisolone as a topical steroid in this case [7, 18].

It is recommended that treatment with TPM for migraine be started with a low dose and gradually increased to the required dosage depending on improvement of the condition and patient tolerability profile. But in this particular patient, reaction appeared to be independent of the dose and duration as the patient had received the minimum therapeutic dose of 25 mg/day and TPM reaction developed within a short duration of treatment [5, 19]. While this is difficult to explain, despite discontinuation of TPM, the cumulative effect may be considered responsible for development of AACG. The mechanism by which TPM causes ciliary body swelling and anterior rotation of the ciliary body is still not clear. The most shared hypothesis remains to be idiosyncratic reaction [13, 14]. Based on the above information, it may be suggested that it is important and appropriate to avoid treatment of AACG with miotics and medications chemically related to sulfa drugs. Initiation of treatment with TPM over 3 days induced AACG on day 8 and instituting treatment reversed the signs and symptoms of AACG and patient was normal after discontinuation of TPM. Based on this fact, the eventual causality as TPM-induced AACG can be confirmed.

However, in this particular patient although history of medication intake revealed treatment with anti-cholinergics for other reasons, patient did not exhibit eye symptoms. Therefore, the mechanisms implicated in development of AACG in this case need further evaluation.

Lastly, the authors wish to point out that the patient in this case is 25 years old, which is young for POAG as the onset is normally seen after 40 years of age [2]. The limitations of this study were that this is a single case report and not a case series, which are preferred. In addition, causality using a standard scale was not used to confirm association between the offending drug and adverse reaction.

CONCLUSION

TPM is frequently used in the treatment of migraine and is reported to increase IOP and as a result has a potential to precipitate AACG in a genetically predisposed person. A single dose may precipitate AACG as an idiosyncratic reaction which is a rare but a very serious adverse reaction and may progress to blindness. It is, therefore, recommended that the physician before prescribing TPM should warn and advise the patient to report any cases of visual disturbances immediately. It is also advisable to monitor the IOP at baseline before initiating treatment with TPM and regularly at weekly intervals thereafter for a month from the time of commencement of medications to prevent glaucoma as one of its serious adverse reactions.

Although this is a widely reported adverse effect of TPM, there are a few questions which remain unanswered. One aspect that could be examined is how exactly sulfa-derived medications such as TPM can cause swelling of ciliary body and eventual anterior rotation of

ciliary body. It would be worth investigating to see if patients who developed AACG with TPM showed a similar reaction to other sulfa-containing compounds. However, in this patient AACG was precipitated specifically with TPM. In addition, considering age of this patient it is unlikely to be POAG.

With recent advances in the field of drug discovery and development, there appears to be a possibility to minimize such undesirable, unexpected, and serious adverse events using safer treatment options in patients with migraine. Alternatively, careful and regular monitoring of patients receiving TPM is important. Finally, with exponential advancement in pharmacogenetics, every patient taking TPM could be considered as a potential candidate for developing AACG, and be screened adequately and appropriately using suitable biomarkers to prevent serious adverse events.

ACKNOWLEDGMENTS

Dr. Kulkarni is the guarantor for this article, and takes responsibility for the integrity of the work as a whole. No funding or medical writing assistance was provided.

Conflict of interest. Chanda Kulkarni, Urmimala Ray Chaudhuri, and Annalakshmi Jagathesan declare no conflict of interest.

Compliance with Ethics Guidelines. All procedures followed were in accordance with the ethical standards of the responsible committee on human experimentation (institutional and national) and with the Helsinki Declaration of 1975, as revised in 2008. Written informed consent was obtained from the patient for which identifying information is included in this case report.

Open Access. This article is distributed under the terms of the Creative Commons Attribution Noncommercial License which permits any noncommercial use, distribution, and reproduction in any medium, provided the original author(s) and the source are credited.

REFERENCES

1. Modi S, Lowder DM. Medications for migraine prophylaxis. *Am Fam Physician*. 2006;73:72–8.
2. Arnone D. Review of the use of topiramate for treatment of psychiatric disorders. *Ann Gen Psychiatry*. 2005;4:5.
3. Rosenfeld WE. Topiramate: a review of preclinical, pharmacokinetic, and clinical data. *Clin Ther*. 1997;19:1294–308.
4. Gawley SD. Topiramate induced acute transient myopia: a case report. *Cases J*. 2009;2:7430.
5. Pai k, Rajashekar P. Glaucoma: Adverse event on use of topiramate in alcohol de-addiction. *Indian J Psychiatry* 2011;53:163–5. Available at: http://www.indianjpsychiatry.org/temp/IndianJPsychiatry532163-1494567_040905.pdf Last accessed: 26 February 2012.
6. Sachi D, Vijaya L. Topiramate induced secondary angle closure glaucoma. *J Postgrad Med*. 2006;52:72–3.
7. Chen TC, Chao CW, Sorkin JA. Topiramate induced myopic shift and angle closure glaucoma. *Br J Ophthalmol*. 2003;87:648–9.
8. Topamax (package insert). Raritan, NJ: Ortho-McNeil Pharmaceutical Inc; 2001.
9. Kisan R, Kisan SR, Anitha OR, Chandrakala SP, Koujalagi RS. Correlation between the intraocular pressure and the blood pressure in different age group. *J Clin Diagn Res*. 2012 (Suppl-2);6:581–5.
10. Jacob A, Thomas R, Koshi SP, Braganza A, Muliylil J. Prevalence of primary glaucoma in an urban South Indian population. *Indian J Ophthalmol*. 1998;46:81–6.
11. Fraunfelder FW, Fraunfelder FT, Keats EU. Topiramate-associated acute, bilateral, secondary angle-closure glaucoma. *Ophthalmology*. 2004;111:109–11.
12. Fraunfelder FW, Fraunfelder FT. Adverse ocular drug reactions recently identified by the National Registry of Drug Induced Ocular Side Effects. *Ophthalmology*. 2004;111:1275–9.
13. Senthil S, Garudadri C, Rao HB, Maheshwari R. Bilateral simultaneous acute angle closure caused by sulphonamide derivatives. A case series. *Indian J Ophthalmol*. 2010;58:248–52.
14. Willett MC, Edward DP. Refractory topiramate-induced angle-closure glaucoma in a man: a case report. *J Med Case Rep*. 2011;5:33.
15. Fuse N. Genetic bases of glaucoma. *Tohoku J Exp Med*. 2010; 8:221:1–10. Available at: https://www.jstage.jst.go.jp/article/tjem/221/1/221_1_1/_pdf Last accessed: 26 February 2012.
16. WuDunn D. Genetic basis of glaucoma. *Curr Opin Ophthalmol*. 2002;13:55–60.
17. Lai JSM, Gangwani RA. Medication-induced acute angle closure attack. Review article. *Hong Kong Med J*. 2012;18:139–45.
18. Spaccapelo L, Leschiutta S, Aurea C, Ferrari A. Topiramate-associated acute glaucoma in a migraine patient receiving concomitant citalopram therapy: a case-report. *Cases J*. 2009; 2:87.
19. Caglar C, Yasar T, Ceyhan D. Topiramate induced bilateral angle-closure glaucoma: low dosage in a short time. *J Ocul Pharmacol Ther*. 2012;28:205–7.

Available at: http://www.jcdr.net/back_issues.asp?issn=0973-709x&year=2012&month=May&volume=6&issue=4&page=581-585&id=2141 Last accessed: 4 March 2013.