Cardiothoracic Anesthesia, Respiration and Airway

Anterior mediastinal tumour identified by intraoperative trans-esophageal echocardiography

Chun-Ming Lin MD,
Jee-Ching Hsu MD

Purpose: To report a child with anterior mediastinal tumour misdiagnosed as pericardial effusion who had been sent to the operating theatre for drainage. After induction of general anesthesia she developed cardio-respiratory collapse. The diagnosis was made with the aid of transesophageal echocardiography (TEE).

Clinical features: A 14-yr-old girl suffered from cough and intermittent fever for one month before admission. Four days before admission, she became orthopneic and was admitted to the intensive care unit. Precordial echocardiography showed an anterior and posterior echolucent space between the pericardium and epicardium that was thought to be a pericardial effusion. She was sent to the operating room for emergency drainage.

After induction of general anesthesia, breath sounds were not heard on the left side of the chest. The patient developed increasing hypoxemia and hypotension despite cardiocentesis. A TEE determined that an anterior mediastinal mass was the cause of her hypoxemia and hypotension. The tumour was debulked and the patient made an uneventful postoperative recovery.

Conclusion: In this case, the correct diagnosis of an anterior mediastinal mass was made with TEE. The place of TEE may be indicated in patients with unexplained hypoxemia and hypotension.

Objectif : Présenter le cas d'une enfant atteinte d'une tumeur médiastinale antérieure, diagnostiquée à tort comme un épanchement péricardique, et qui a été dirigée vers la salle d'opération pour y subir un drainage. Après l'induction de l'anesthésie générale, elle a présenté un collapsus cardio-respiratoire. Le diagnostic a été fait à l'aide de l'échocardiographie transœsophagienne (ETO).

Éléments cliniques : Une fillette de 14 ans souffrait de toux et de fièvre intermittente depuis un mois. Quatre jours avant son entrée à l'hôpital, elle est devenue orthopnéique et a été admise à l'unité des soins intensifs. L'échocardiographie précordiale a démontré un espace entre le péricarde et l'épicarde qui a fait penser à un épanchement péricardique. Elle a été dirigée vers la salle d'opération pour un drainage d'urgence.

Après l'induction de l'anesthésie, le murmure vésiculaire n'était pas audible du côté gauche du thorax. La patiente a présenté une hypoxémie et une hypotension croissantes malgré la cardiocentèse. Une ETO a identifié une masse médiastinale antérieure comme cause de l'hypoxémie et de l'hypotension. La tumeur a été réséquée et la patiente a connu une récupération postopératoire sans incident.

Conclusion : Le bon diagnostic de masse médiastinale antérieure a été fait ici grâce à l'ETO. L'utilisation de l'ETO est indiquée dans les cas d'hypoxémie et d'hypotension inexpliquées.

From the Department of Anesthesiology, Chang Gung Memorial Hospital, 5 Fu-Shin St, Kweishan, Taoyuan, Taipei, Taiwan, R.O.C.
Address correspondence to: Chun-Ming Lin MD; Phone: 886-3-3281200, ext.2389; Fax: 886-3-3281200, ext.2793;
E-mail: sam2498@adm.cgmh.com.tw
Accepted for publication October 1, 2000.

WE describe a case of suspected pericardial effusion that developed cardio-respiratory collapse after induction of anesthesia. The correct diagnosis of anterior mediastinal tumour was made by TEE during operation.

Clinical Features

A 14-yr-old girl, 43 kg, suffered cough and intermittent fever for one month before admission to hospital. Four days before admission, she became orthopneic and was admitted to the intensive care unit. The pediatrician heard a systolic murmur over the left upper sternal border. Precordial echocardiography showed an anterior and posterior sonolucent space between the pericardium and epicardium that was thought to be a pericardial effusion (Figure 1). She was transferred to the operating room for emergency subxyphoid drainage.

In the operating room, prior to oxygenation, standard monitors revealed heart rate of 118 beat·min^{-1}, blood pressure 98/61 mmHg, respiratory rate 28 bpm, and the pulse oximetry 93%. The patient was lying in a semi-sitting position and received and anesthesia was induced with 5 mg midazolam, 5 mg vecuronium, and 150 g fentanyl. The trachea was intubated two minutes later with 6.0 cuffed endotracheal tube fixed at 18 cm at the angle of the mouth. Anesthesia was maintained with O_2 100% and isoflurane 1.0% . Breath sounds were not heard on the left side of the chest, the endotracheal tube was withdrawn 1 cm, but the situation did not change. The inspiratory pressure reached 33 cm H_2O. Central venous cannulation via the right internal jugular vein showed central venous pressure (CVP) of 20 cmH_2O. Fibreoptic examination showed the lumen of the left bronchus was obstructed by external compression and, at the same time, the surgeon performed subxyphoid drainage of 150 ml bloody fluid. Pulse oximetry gradually decreased from 100% to 70%, the blood pressure from to 70/40 mmHg and the CVP increased to 29 cm H_2O. Echocardiography demonstrated a tumour-like echo-lucent structure surrounded the heart that an anterior mediastinal tumour had this appearance (Figure 2). We tried to place the patient in the right lateral position and then in a semi-sitting position, but pulse oximetry did not increase. As the patient's condition deteriorated, the surgeon performed a sternotomy and pulse oximetry increased to 100% in ten minutes. A huge tumour enwrapped the heart, compressing the superior vena cava and the left main bronchus. Debulking of the mass was performed to relieve the cardiac and bronchial compression. After the operation, the patient was sent to the intensive care unit. The endotracheal tube was removed two days later. Pathological examination showed malignant lymphoma. She was referred to the pediatric oncologist for chemotherapy.

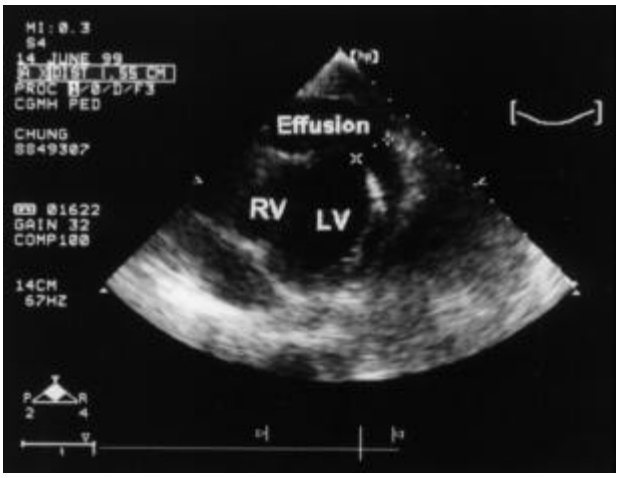

FIGURE 1 The sonolucent space before the heart mistook as the pericardial effusion.

FIGURE 2 An echolucent tissue surrounded the heart. There were some echogenic densities inside the tissue and proved to be fibrous tissues after debulking the mass.

Discussion

Intraoperative TEE is a valuable monitoring and diagnostic tool in hemodynamically unstable patients. According to the practical guidelines for perioperative transesophageal echocardiography reported by the American Society of Anesthesiologists and the Society of Cardiovascular Anesthesiologists, the use of TEE is

considered a category one indication in patients with unexplained refractory hypotension.[1] Although, other monitoring devices can provide some of this information, TEE offers important advantages because it produces real-time imaging of the heart and nearby structures. The procedure is generally safe, but insertion and manipulation can produce pharyngeal and laryngeal trauma, dental injuries, esophageal trauma, bleeding and arrhythmia.

Echocardiography is an accepted noninvasive technique for detecting pericardial effusion but a pericardial tumour might mimic pericardial effusion by echocardiography.[2,3] The echocardiographic diagnosis of a pericardial effusion in the presence of suspected neoplastic infiltration is difficult because the sonolucent space may also reflect neoplastic involvement.

In the pediatric population the mediastinum is the primary site of involvement in 16-36% of non-Hodgkin's lymphoma and 54-81% of Hodgkin's lymphoma.[4] Rapidly evolving symptoms of respiratory compromise or superior vena cava syndrome represent true emergencies that require prompt treatment.[5,6]

Airway compression due to a mediastinal mass may occur immediately after induction of general anesthesia, after nondepolarizing muscle relaxants as in this case, or after tracheal extubation. Changing the patient's position to move the tumour weight off the trachea or main bronchus may improve oxygenation, but did not do so in our case perhaps because of the huge tumour mass. The use of cardiopulmonary bypass or extracorcorporeal membrane oxygenation in patients with refractory hypoxemia and hypotension is another method that might be considered.[7] Establishing the anatomical and functional involvement of the tumour before operation could avoid unnecessary danger in the perioperative phase.[8,9]

In summary, this report describes the emergency anesthesia management of a 14-yr-old girl scheduled for pericardiocentesis. Following anesthesia induction and tracheal intubation, the patient developed increasing hypoxemia and hypotension despite cardiocentesis. Transesophageal echocardiography demonstrated that an anterior mediastinal mass was the cause of her hypoxemia and hypotension rather than a pericardial effusion. Sternotomy to debulk a mediastinal lymphoma was life saving. This case report suggests that transesophageal echocardiography has a role as an intraoperative diagnostic technique.

References

1 Practice guidelines for perioperative Transesophageal Echocardiography. A report by the American Society of Anesthesiologists and the Society of Cardiovascular Anesthesiologists task force on TEE. Anesthesiology 1996; 84: 986–1006.

2 *Allen JW, Harrison EC, Camp JC, Borsari A, Turnier E, Lau FYK.* The role of serial echocardiography in the evaluation and differential dignosis of pericardial disease. Am Heart J 1977; 93: 560–7.

3 *Millman A, Meller J, Motro M, et al.* Pericardial tumor or fibrosis mimicking pericardial effusion by echocardiography. Ann Intern Med 1977; 86: 434–6.

4 *Ferrari LR, Bedford RF.* General anesthesia prior to treatment of anterior mediastinal mass in pediatric cancer patients. Anesthesiology 1990; 72: 991–5.

5 *Greengrass R.* Anesthesia and mediastinal masses (Letter). Can J Anaesth 1990; 37: 596.

6 *Northrip DR, Bohman BK, Tsueda K.* Total airway occlusion and superior vena cava syndrome in a child with an anterior mediastinal tumor. Anesth Analg 1986; 65: 1079–82.

7 *Takeda S, Miyoshi S, Omori K, Okumura M, Matsuda H.* Surgical rescue for life threatening hypoxemia caused by a mediastinal tumor. Ann Thorac Surg 1999; 68: 2324–6.

8 *Tinker TD, Crane DL.* Safety of anesthesia for patients with anterior mediastinal masses (I) (Letter). Anesthesiology 1990; 73: 1060.

9 *Zornow MH, Benumof JL.* Safety of anesthesia for patients with anterior mediastinal mass (II) (Letter). Anesthesiology 1990; 73: 1061.