Flumazenil as a diagnostic tool in the differential diagnosis of coma in a critically ill patient

Henry Sprenger BScPhm,* Michael D. Sharpe MD FRCPC,† Richard S. McLachlan MD, FRCPC‡

The purpose of this report is to describe the use of flumazenil as a diagnostic aid in the differential diagnosis of coma in a patient with an inadvertent overdose of benzodiazepines. We report a patient with suspected septic encephalopathy whose level of consciousness markedly improved following flumazenil administration. Subsequent analysis revealed the presence of benzodiazepines and their metabolites in the blood and urine although the patient had not received benzodiazepines for over two weeks. The critically ill patient with multiorgan failure may have considerable derangement of benzodiazepine metabolism; therefore, if an obtunded patient's level of consciousness improves following flumazenil administration, benzodiazepine intoxication must be considered.

Cette observation se rapporte à l'utilisation du flumazénil pour le diagnostic d'un coma chez un patient qui a reçu une surdose de benzodiazépines. Le degré de conscience du patient chez qui on suspectait une encéphalopathie septique s'améliore après l'administration de flumazénil. L'analyse sanguine et urinaire révèle par la suite la présence de métabolites des benzodiazépines malgré le fait qu'on ne lui ait pas administré de benzodiazépine depuis deux semaines. Ce malade grave avec défaillance multiviscérale aurait pu souffrir d'une altération du métabolisme des benzodiazépines. Toutefois, l'amélioration notée après l'administration du flumazénil milite en faveur d'un intoxication aux benzodiazépine.

Key words
ANTAGONISTS: benzodiazepines, flumazenil;
COMPLICATIONS: coma;
INTENSIVE CARE:
INFECTION: septicaemia.

From the W.E. Spoerel Intensive Care Unit, University Hospital, and Program in Critical Care, Departments of Anaesthesia†, Pharmacy*, and Clinical and Neurological Sciences‡, University Hospital, University of Western Ontario, London, Ontario.

Address correspondence to: Dr. M.D. Sharpe, Department of Anaesthesia, University Hospital, P.O. Box 5339, London, Ontario N6A 5A5.

Accepted for publication 1st October, 1993.

Flumazenil, a specific benzodiazepine antagonist, has a high affinity for and competitively binds to the benzodiazepine-GABA (gamma aminobutyric acid) receptor complex.[1,2] Gamma aminobutyric acid is a major inhibitory CNS transmitter, therefore stimulation of this receptor complex by a benzodiazepine agonist results in decreased neural excitability. Flumazenil is capable of reversing or blocking the CNS effects of benzodiazepines. It has been used for antagonism of general anaesthesia induced or maintained with benzodiazepines[3-5] for the reversal of benzodiazepine sedation, in short, diagnostic and therapeutic procedures,[6] for the diagnosis and/or management of deliberate or accidental overdosages,[7-11] and has improved neurological function in patients with Grade III–IV hepatic encephalopathy.[12-15] We report a case of a patient with suspected septic encephalopathy whose level of consciousness improved markedly following flumazenil administration; subsequent blood analysis revealed diazepam and active metabolites two weeks following discontinuation of benzodiazepine administration.

Case report

A 77-yr-old man was admitted for elective revision of a right knee prosthesis. Immediately before surgery, the patient developed peritonitis with septic shock requiring resuscitation and ventilatory support in the ICU. He underwent emergency laparotomy for drainage of a ruptured peridiverticular abscess and resection of the sigmoid colon and a portion of the small bowel. Postoperatively, cardiac studies indicated the patient had sustained a perioperative myocardial infarction and mechanical ventilation was required for 22 days during the gradual recovery from his septic process. Two days after his discharge from the ICU (post-op day 25), the patient required readmission to the ICU with obtundation and septic shock secondary to a urinary tract infection. At that time, in-

dices of renal and hepatic function were normal (serum creatinine 76 $\mu mol \cdot L^{-1}$, BUN 6.1 $\mu mol \cdot L^{-1}$, ALT 32 $U \cdot L^{-1}$, AST 19 $U \cdot L^{-1}$, alk phos 86 $U \cdot L^{-1}$). The patient continued to have recurrent febrile and hypotensive episodes and required mechanical ventilation. Renal function gradually deteriorated and by day 65, serum creatinine and BUN had risen to 223 $\mu mol \cdot L^{-1}$ and 34.6 $\mu mol \cdot L^{-1}$ respectively.

Indices of liver function indicated a mild increase (ALT 44 $U \cdot L^{-1}$ (normal 5–30) AST 55 $U \cdot L^{-1}$ (normal 10–30), alk phos 362 (normal 18–113)). Prothrombin time was normal (10.9 sec). The patient became markedly jaundiced with a bilirubin increasing from 25.1 $\mu mol \cdot L^{-1}$ on day one to 225.8 $\mu mol \cdot L^{-1}$ by day 66. During a three-week period, the patient became confused and less cooperative until gradually he became obtunded and unresponsive. A standard 16 channel EEG taken on day 42 showed burst suppression and a theta coma pattern consistent with a severe encephalopathy. A lumbar puncture was performed which revealed unremarkable CSF.

During the course of his ICU admission, the patient had received numerous doses of narcotic analgesics and sedatives which included diazepam (1–2 mg q15 min, *iv*) lorazepam (1 mg q15 min, *iv*), midazolam (2–5 mg, *iv*), and haldol (2.5–5 mg, *im*) on a *prn* basis. All benzodiazepines were discontinued on day 51. During the five days prior to discontinuing benzodiazepines, the patient had received total doses of midazolam – 16 mg, diazepam – 12.5 mg and lorazepam – 7 mg. Repeat EEG showed no improvement and since a burst suppression pattern is also consistent with benzodiazepine intoxication, a qualitative benzodiazepine screen of blood and urine was performed on day 64. On day 65, a single *iv* injection of flumazenil (Anexate R Hoffman-Laroche, 2 mg) was given over one minute during continuous EEG recording. Initially, the EEG revealed generalized delta and burst suppression consistent with coma from a diffuse encephalopathy. Within 30 sec of the injection of flumazenil the patient's eyes opened wide, he became alert and nodded appropriately to questions. The EEG tracing showed that the injection of flumazenil induced immediate electro-encephalographic arousal which persisted for approximately five hours (Figure). The patient gradually became more obtunded and eventually returned to his pre-flumazenil state (unresponsive to painful stimuli). On day 86, the patient died of multiorgan failure secondary to sepsis. Although two weeks had passed since this patient had received benzodiazepines, both serum and urine were positive for benzodiazepines. In the serum, diazepam and its metabolite nordiazepam were detected, with nordiazepam predominating, indicating a minimum concentration of 1.8 $\mu mol \cdot L^{-1}$ (0.5 $ng \cdot ml^{-1}$). In the urine,

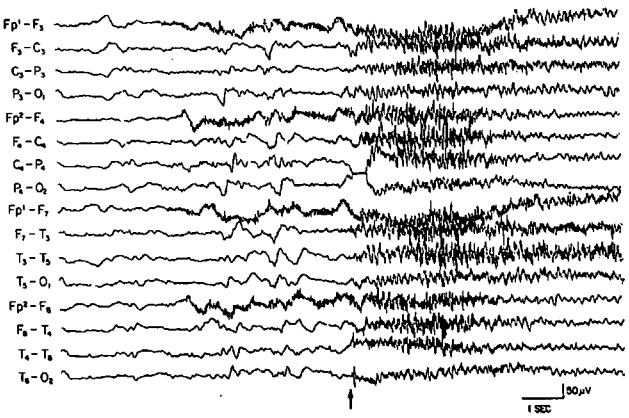

FIGURE EEG during flumazenil infusion, patient awakens from coma (arrow) 30 seconds after infusion of drug begins.

only oxazepam, a metabolite of diazepam, was detected, indicating a minimum concentration of 150 $nmol \cdot L^{-1}$ (42 $ng \cdot ml^{-1}$). The therapeutic serum levels of diazepam and oxazepam are reported as 100–500 $ng \cdot ml^{-1}$ and 300–400 $ng \cdot ml^{-1}$ respectively, and therapeutic blood levels vary considerably from patient to patient.[16-18]

Discussion

It is not uncommon for the febrile septic patient to develop an altered mental state. Septic encephalopathy, a term used to refer to the syndrome of altered brain function, is related to the presence of microorganisms or their toxins in the blood.[19] Many factors may act alone or in combination and result in brain dysfunction. These include CNS infections, direct endotoxin effects, reduced cerebral perfusion, metabolic derangements, liver insufficiency and multi-system organ failure.[20] These patients present with a wide range of symptoms including agitation, disorientation, obtundation, stupor and in the patient with severe encephalopathy, as demonstrated in our case, coma.

The theta coma and burst suppression pattern on EEG was suggestive of anoxic, septic or metabolic encephalopathy including severe drug intoxication. It was therefore necessary to determine the aetiology of this patient's responsive state. Although the EEG findings are often non-specific in this patient population, the EEG is important to rule out status epilepticus as a cause of coma since it may not be associated with grand mal seizures. In light of the positive plasma and urine benzodiazepine levels it was decided to use the benzodiazepine antagonist flumazenil to determine if benzodiazepine intoxication was contributing to his neurological dysfunction.

The immediate and dramatic clinical response that was seen after flumazenil suggested that the largest factor contributing to this patient's comatose state was the presence

of benzodiazepines. The sudden arousal from deep coma to normal wakefulness demonstrated by the EEG confirmed the clinical impression. Since flumazenil has no direct effect on the EEG,[21] the arousal response could only be attributed to antagonism of benzodiazepine receptors. However, apart from an indirect effect of the patient's hepatic disease decreasing benzodiazepine metabolism, it was possible that the patient's depressed level of consciousness was due to his underlying hepatic failure since benzodiazepine-like agonists have been proposed to be synthesized by the liver in hepatic failure. For example, previous reports showing improvement in neurological function following flumazenil administration, occurred in patients who presented with acute deterioration of hepatic function.[22-24] Similar results have also been shown in animal models of fulminant hepatic failure.[25] However, our patient demonstrated only mild increases in hepatic enzymes and the prothrombin time, a maker of hepatic function, was normal. As well, clinical improvement in neurological function with flumazenil has occurred only in patients with significant hepatic dysfunction, who present with Grade III–IV hepatic coma. The clinical improvement seen in patients with grade I–II hepatic encephalopathy is less impressive and often not evident.[12-15] We feel, therefore, that the cause of our patient's comatose state was primarily benzodiazepine intoxication, as opposed to his underlying mild hepatic disease.

Benzodiazepines were detected in the patient's serum and urine two weeks after any of these agents had been given. Both diazepam and its metabolite nordiazepam were present in the blood and oxazepam, a metabolite of diazepam, was present in the urine. Unfortunately, only a qualitative assay was available. It is important to note that the detection process for oxazepam in the urine initially requires hydrolysis of the glucuronide bond with oxazepam thereby allowing oxazepam to be extracted. Since this hydrolysis process does not occur during blood analysis, oxazepam would not be detected in the serum.

Since benzodiazepines depend on hepatic metabolism and renal excretion for their clearance, disturbance of hepatic and renal function, coupled with ongoing administration of diazepam and lorazepam would lead to accumulation of benzodiazepines within the fat stores of the body. This could then serve as a potential reservoir for the release of drug, even two weeks after the last dose had been given. The effect of flumazenil is quite rapid and the duration of action is short. Since flumazenil has no effect on the bioavailability, plasma concentrations or half-life of the benzodiazepine agonists,[2,26] its actions are solely the result of its binding interaction with the benzodiazepine receptor. For instance, the half-life of flumazenil is between 0.7 and 1.3 hr while the half-life of diazepam can be as long as 50 hr,[18] with active metabolites eliciting longer half-lives. For example, the formation of nordiazepam from diazepam can extend biological half-life threefold.[18] Therefore, the re-emergence of the sedative effects of benzodiazepines and their active metabolites may occur once the effects of flumazenil have dissipated, as demonstrated in this case. If the patient were stable and ready for tracheal extubation, a continuous infusion of flumazenil to maintain an appropriate level of consciousness would have been considered.

In conclusion, this case report describes the use of flumazenil as a diagnostic tool in a septic patient whose comatose state was due to an unrecognized benzodiazepine intoxication. The EEG provided an objective measure of the patient's response to flumazenil. Flumazenil administration is useful as a diagnostic aid in critically ill patients with a depressed level of consciousness and may identify benzodiazepine intoxication in a patient whose metabolism and clearance of benzodiazepines is impaired.

References

1 *Karavokiros KAT, Tsipis GB.* Flumazenil: a benzodiazepine antagonist. DICP Ann Pharmacother 1990; 24: 976–81.

2 *Klotz U.* Drug interactions and clinical pharmacokinetics of flumazenil. Eur J Anaesthesiol 1988; Suppl 2: 103–8.

3 *Alon E, Baitella L, Hossli G.* Doubld-blind study of the reversal of midazolam-supplemented general anaesthesia with RO 15–1788. Br J Anaesth 1987; 59: 455–8.

4 *Zuurmond WWA, van Leeuwen L, Helmers JHJH.* Recovery from fixed-dose midazolam-induced anaesthesia and antagonism with flumazenil for outpatient arthroscopy. Acta Anaesthetsiol Scand 1989; 33: 160–3.

5 *Skielboe M, Andersen P, Weber M, Jarnvig I-L, Jørgensen B, Christiansen C.* Antagonism of diazepam sedation by flumazenil. Br J Anaesth 1989; 63: 554–7.

6 *Sanders LD, Piggott SE, Isaac PA, et al.* Reversal of benzodiazepine sedation with the antagonist flumazenil. Br J Anaesth 1991; 66: 445–53.

7 *Höjer J, Baehrendtz S, Matell G, Gustafsson LL.* Diagnostic utility of flumazenil in coma with suspected poisoning: a double blind, randomised controlled study. BMJ 1990; 301: 1308–11.

8 *Votey SR, Bosse GM, Bayer MJ, Hoffman JR.* Flumazenil: a new benzodiazepine antagonist. Ann Emerg Med 1991; 20: 181–8.

9 *Ume EOC, Gelb AW.* Reversal of iatrogenic diazepam overdose with flumazenil. Clin Pharm 1988; 7: 614–6.

10 *Winkler E, Almog S, Kriger D, Tirosh MS, Halkin H, Ezra D.* Use of flumazenil in the diagnosis and treatment of patients with coma of unknown etiology. Crit Care Med 1993; 21: 538–42.

11 *Burkhart KK, Kulig KW.* The diagnostic utility of flumazenil (a benzodiazepine antagonist) in coma of unknown etiology. Ann Emerg Med 1990; 19: 319–21.
12 *Grimm G, Katzenschlager R, Schneeweiss B, et al.* Improvement of hepatic encephalopathy treated with flumazenil. Lancet 1988; 2: 1392–4.
13 *Scollo-Lavizzari G, Steinmann E.* Reversal of hepatic coma by benzodiazepine antagonist (Ro 15–1788) (Letter). Lancet 1985; 1: 1324.
14 *Bansky G, Meier PJ, Ziegler WH, Walser H, Schmid M, Huber M.* Reversal of hepatic coma by benzodiazepine antagonist (Ro 15–1788) (Letter). Lancet 1985; 1: 1324–5.
15 *Bansky G, Meier PJ, Riederer E, Walser H, Ziegler WH, Schmid M.* Effects of the benzodiazepine receptor antagonist flumazenil in hepatic encephalopathy in humans. Gastroenterology 1989; 97: 744–50.
16 *Booker HE, Celesia GG.* Serum concentrations of diazepam in subjects with epilepsy. Arch Neurol 1973; 29: 191–4.
17 *Bowden CL, Fisher JG.* Relationship of diazepam serum level to antianxiety effects. J Clin Psychopharmacol 1982; 2: 110–4.
18 *Gilman AG, Goodman LS, Rall TW, Murad F (Eds.). In:* Goodman and Gilman's The Pharmacological Basis of Therapeutics. 7th ed. New York: MacMillan Publishing Company, 1985.
19 *Young GB.* The encephalopathy associated with sepsis. Annal of the Royal College of Physicians and Surgeons of Canada. 1986; 19: 279–82.
20 *Sprung CL, Cerra FB, Freund HR, et al.* Amino acid alterations and encephalopathy in the sepsis syndrome. Crit Care Med 1991; 19: 753–7.
21 *Breimer LTM, Hennis PJ, Burm AGL, et al.* Pharmacokinetics and EEG effects of flumazenil in volunteers. Clin Pharmacokinet 1991; 20: 491–6.
22 *Ferenci P, Grimm G, Meryn S, Gangl A.* Successful long-term treatment of portal-systemic encephalopathy by the benzodiazepine antagonist flumazenil. Gastroenterology 1989; 96: 240–3.
23 *Gyr K, Meier R.* Flumazenil in the treatment of portal systemic encephalopathy – an overview. Intensive Care Med 1991; 17: S39–S42.
24 *Mullen KD, Szauter KM, Kaminsky-Russ K.* "Endogenous" benzodiazepine activity in body fluids of patients with hepatic encephalopathy. Lancet 1990; 336: 81–3.
25 *Gammel SH, Basile AS, Geller D, Skolnick P, Jones EA.* Reversal of the behavioural and electrophysiological abnormalities of an animal model of hepatic encephalopathy by benzodiazepine receptor ligands. Hepatology 1990; 11: 371–8.
26 *Amrein R, Hetzel W.* Pharmacology of drugs frequently used in ICUs: midazolam and flumazenil. Intensive Care Med 1991; 17: S1–S10.