

## Brief Review

# Ulnar nerve palsy at the elbow after general anaesthesia

Luc Perreault MD, Pierre Drolet MD FRCPC,  
Juliana Farny MD

*Ulnar nerve palsy is a recognized complication of general anaesthesia. Many authors have reported several series of patients and found different incidences. In this literature review, the patho-physiology of the lesion and the anatomical characteristics of the cubital tunnel at the elbow are described together with its related conditions "cubital tunnel compression syndrome" and "recurrent ulnar nerve dislocation at the elbow." A precise and early diagnosis should be made using electromyography to determine the exact location of the lesion and the precise time-relationship of the pathology. The importance of careful positioning of the patient under anaesthesia in the prevention of ulnar nerve palsy is stressed. Unfortunately, treatment of the established lesion gives, at best, mixed results.*

*La paralysie du nerf cubital est une complication connue à l'anesthésie générale. Plusieurs auteurs ont rapporté des séries de malades et ont trouvé des incidences variables. Dans cette revue de la littérature, nous décrivons la physio-pathologie de cette lésion et les caractéristiques anatomiques du tunnel cubital au niveau du coude. Nous notons l'importance de la coexistence de certaines entités comme le « syndrome de compression au niveau du tunnel cubital » et la « luxation récidivante du nerf cubital au niveau du coude ». Un diagnostic rapide et précis à l'aide de l'électromyographie peut préciser la localisation exacte de la lésion et en déterminer le début d'apparition. Nous insistons sur l'importance du positionnement des malades sous anesthésie dans la prévention des paralysies du nerf cubital, le traitement de lésions établies donnant des résultats décevants.*

### Key words

COMPLICATIONS: neurological, palsy;  
NERVE: damage (postoperative), ulnar.

From the Department of Anaesthesia, Maisonneuve-Rosemont Hospital, University of Montreal, Montreal, Quebec.

Address correspondence to: Dr. Luc Perreault, Department of Anaesthesia, Maisonneuve-Rosemont Hospital, 5415 boul. de l'Assomption, Montreal, Quebec, H1T 2M4.

Accepted for publication 12th January, 1992.

Ulnar nerve palsy is a recognized complication of general anaesthesia. Kroll *et al.*,<sup>1</sup> in a Closed Claims Study of the American Society of Anesthesiologists, recently reported 227 cases of nerve injury out of a total of 1,541 charts reviewed. Ulnar neuropathy represented one third of all claims related to nerve injuries. Alvine *et al.*<sup>2</sup> in a series of 6538 patients followed through surgery and convalescence found 17 patients (0.26%) who developed ulnar nerve palsy. Ekerot<sup>3</sup> between 1973–1976 found 19 patients with ulnar nerve injury after recent, otherwise uncomplicated anaesthetic procedures. The nerve injury was localized to the cubital tunnel region in all patients. Some forms of surgery may put patients at particular risk. Wey *et al.*<sup>4</sup> studied prospectively 52 patients undergoing anaesthesia for cardiac surgery and found a 61% incidence of ulnar nerve conduction velocity slowing due to compression at the elbow during surgery.

In the United States, payment for claims related to ulnar nerve injury, although not as high as for non-nerve injury are, nonetheless, considerable. Kroll. *et al.*<sup>1</sup> reported payments from \$2,000 to \$330,000 with a median of \$15,000. The author's personal expert's legal experience with this problem was different, six cases being abandoned by the patients due to difficulty in proving negligence on the part of the anaesthetist.

### Pathophysiology

The ulnar nerve is prone to damage because of its position, particularly in the cubital tunnel at the elbow. Trauma may produce three types of injury:<sup>5</sup>

- 1 *Neuropraxia*: Temporary injury followed by rapid recovery. Only myelin degeneration is noted at the site of the trauma.
- 2 *Axonotmesis*: Destruction of the axon but not of the supporting matrix. Usually the axon regenerates spontaneously, leading to complete restoration of function.
- 3 *Neurotmesis*: Involves severe crushing, avulsion, or severance of the nerve. This leads to the formation of a neuroma with loss of function of the nerve.  
The mechanism by which the nerve may be injured

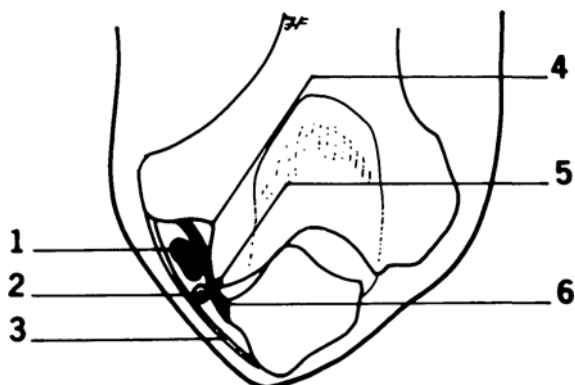


FIGURE 1 Anatomical disposition of cubital tunnel and its content (right elbow flexed): (1) ulnar nerve; (2) ulnar collateral artery; (3) triangular arcuate ligament; (4) medial epicondylar groove; (5) medial lip of the trochlea; (6) medial ligament of the elbow.

differs according to the nature of the trauma. Three causes can be identified:

- 1 Complete section of the nerve which is unlikely during anaesthesia.
- 2 Elongation when the elbow is flexed, even within normal range of arm movement.
- 3 Compression causing anoxia distal to the pressure site or damage directly at the site. The latter is probably the more important since simple ischaemia rarely causes damage, e.g., distal to limb tourniquet.

Compression may be acute or chronic.<sup>6</sup> Compression of short duration puts the limb "asleep" and it recovers immediately when the compression ceases. This seems to be caused by local ischaemia. When considerable compression is maintained for a long time, a local demyelinating lesion is induced and recovery may take weeks or months. It is noteworthy that most of our understanding comes from studies using a tourniquet to induce pressure and this may be of limited use in examining the problem of post-anaesthetic ulnar nerve damage.

#### Causes of post-anaesthetic ulnar nerve lesions at the elbow

##### Predisposing factors

- 1 Anatomy: The ulnar nerve, accompanied by the ulnar collateral artery, passes through the cubital tunnel at the elbow (Figure 1) during its course from the arm to the forearm. The floor of the tunnel is the medial ligament of the elbow and, deep to this, the medial lip of the trochlea and the medial epicondylar groove. The triangular arcuate ligament forms the roof and extends from the medial epicondyle to the medial aspect of the olecranon, thus bridging the two heads of the flexor carpi ulnaris muscle. The capacity of the tunnel is

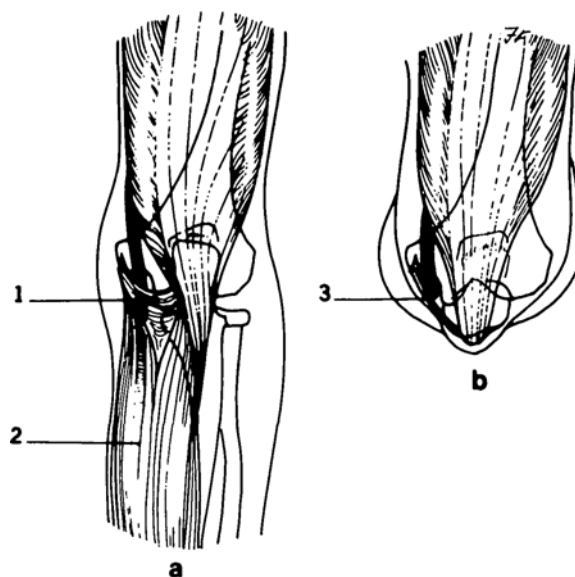


FIGURE 2 Cubital tunnel in (a) extension and (b) 90° flexion: (1) slack arcuate ligament; (2) flexor carpi ulnaris; (3) taut arcuate ligament.

maximal in elbow extension, when the arcuate ligament is slack. At 90° degree of elbow flexion, the proximal edge of the arcuate ligament becomes taut (Figure 2). Measurements on cadaveric specimens<sup>7</sup> have shown the distance between the humeral and ulnar attachments of the arcuate ligament lengthens by five millimeters for each 45° of flexion.

- 2 The anatomy may be modified in normal individuals or as a result of pathological lesions. Childress *et al.*<sup>8</sup> in 1956 described the "recurrent ulnar nerve dislocation at the elbow" which is probably caused by a congenital laxity of the supporting ligaments. Usually it remains asymptomatic but the nerve is prone to injury even with trivial trauma. The syndrome is characterized by hypermobility and is classified in two types:
  - (a) incomplete dislocation of the ulnar nerve where the nerve moves out of the postcondylar groove on to the tip of the humeral epicondyle when the elbow is completely flexed.
  - (b) complete dislocation of the ulnar nerve where the nerve has a greater excursion than in the type A and passes across and anterior to the epicondyle when the elbow is flexed to more than 90° (Figure 3). Among the 16.2% of the normal surgical patients with this anomaly, 121 of 162 had a recurrent dislocation of type A and 41 had type B. Thirty-four of those patients were found to have associated ulnar neuritis. Four of them became symptomatic following surgery.
- 3 Wadsworth *et al.*<sup>9</sup> and Miller<sup>10</sup> described the "Cubital

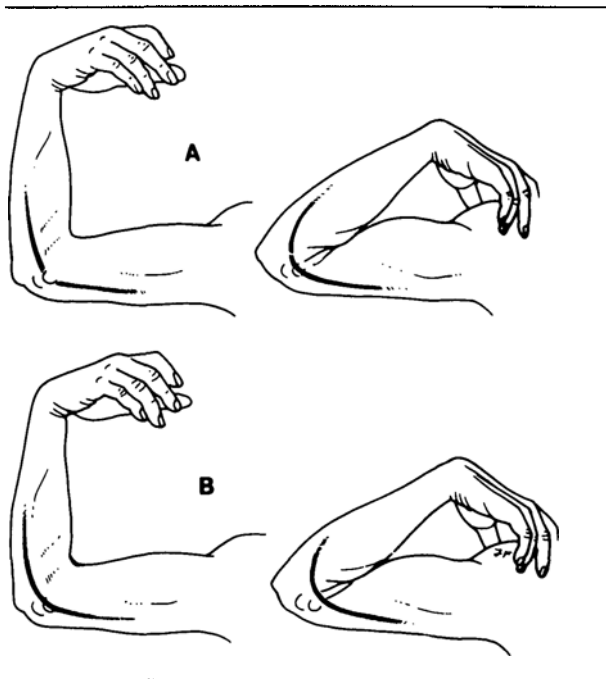


FIGURE 3 Recurrent ulnar nerve dislocation at the elbow: Type A: incomplete dislocation; Type B: complete dislocation. (Adapted from: Childress H.M.<sup>8</sup>)

*tunnel compression syndrome*," which is an ulnar neuropathy caused by compression in the cubital tunnel. The compression may be acute or chronic and may result in partial crippling of the hand. This syndrome is caused by compression of the nerve under the aponeurosis which connect the two heads of flexor carpi ulnaris, produces swelling of the nerve and predisposes it to ischaemia, but without obvious bone deformity. Miller and Camp<sup>11</sup> stated that postoperative ulnar neuropathy was frequently related to the cubital tunnel syndrome. The cubital tunnel syndrome should be distinguished from "*tardy ulnar palsy*" that is caused by obvious bone deformity.<sup>12</sup>

- 4 Metabolic problems and chronic illness such as diabetes mellitus, alcoholism, vitamin deficiency and anaemia may predispose to postoperative ulnar lesions, but their importance is not well defined or understood. Even neurological diseases with polyneuropathies were not convincingly associated with post-anaesthesia cubital lesions except for Charcot-Marie-Tooth and Dejerine-Sottas diseases.<sup>13</sup>
- 5 Occupation or personal habits such as frequent leaning on the elbow could lead to ulnar nerve palsy at the elbow<sup>7,14</sup> possibly by creating a sub-clinical cubital tunnel syndrome.

#### *Mechanism of acute lesion*

The position of the patient may be the cause of com-

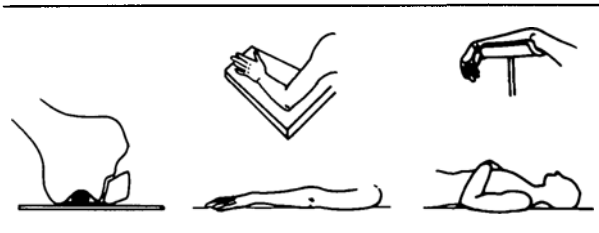


FIGURE 4 Positions associated with compression applied directly on the cubital tunnel. (Modified from: Wadsworth T.G.<sup>7</sup>)

pression of the ulnar nerve at the cubital tunnel at the time of anaesthesia<sup>6,7,11,15-18</sup> but it may occur without predisposing factors. Anaesthesia abolishes the normal protective neuromuscular and vasomotor responses<sup>5,19</sup> and some positions are particularly prone to produce injury (Figure 4). All cause direct compression on the roof of cubital tunnel. Kroll *et al.*<sup>1</sup> observed that men are three times more likely than women to suffer a post-anaesthesia ulnar injury and they speculated that it may be caused by an anatomical predisposition associated with the male body habitus.

The length of the surgery may not be a major factor since of the 19 cases of postoperative ulnar neuropathy reported by Ekerot,<sup>3</sup> many occurred after a routine surgical procedure lasting less than two hours.

Many cases of tourniquet-related nerve damage have been described in men and baboons<sup>20,21</sup> but they usually have a good prognosis. It has been suspected that systemic hypotension, hypoxia and cooling associated with extra corporeal circulation may worsen the prognosis of an already jeopardized nerve.

#### **Diagnosis**

When a postoperative ulnar neuropathy is suspected the history should focus on the predisposing factors, a description of symptoms and the timing of their onset. Anaesthesia chart review may reveal if the position of the patient has been contributory. Physical examination should focus on sensory deficits or paraesthesia in the territory of the ulnar nerve in the hand. Motor deficits, paresis or paralysis, should be looked for. Wasting of the hypothenar and adductor pollicis muscle may be seen and, in severe cases, there is clawing of the ring and little finger (Figure 5). Sometimes, there is sometimes local tenderness over the cubital tunnel. Palpation and elbow flexion may elicit paraesthesia in the cubital distribution<sup>7</sup> and the swollen nerve may be felt.

Electromyography, apart from confirming the location of the lesion, is important in assessing the extent of muscle damage.<sup>22</sup> It is also helpful in distinguishing between complications due to trauma under anaesthesia and those which are coincidental or due to preexisting disease or

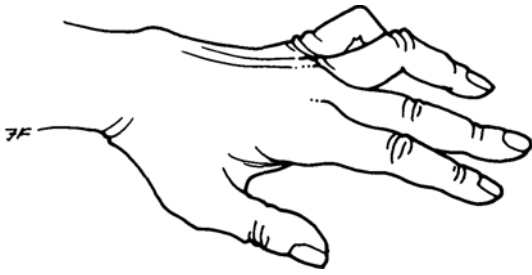


FIGURE 5 Ulnar nerve damage resulting in severe palsy with clawing of the ring and middle finger.

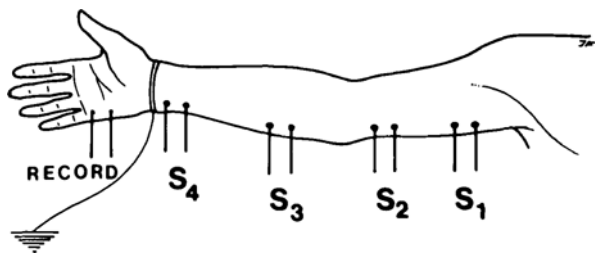


FIGURE 6 Positions of EMG electrodes to locate the exact site of ulnar nerve compression. (Adapted from Eisen A.<sup>22</sup>)

injury.<sup>5</sup> If the EMG is performed immediately after the onset of symptoms, it is possible to determine whether or not the neuropathy was present preoperatively because the signs of denervation resulting from acute injury appear 18 to 21 days after the event and are limited to a specific nerve distribution.<sup>5</sup> It is important to perform a bilateral EMG for comparison, and to repeat it after 21 days to determine the time relationship precisely. It should also be repeated after three to six months to follow the evolution of the lesion. A detailed description of the technique used (voltage and conduction velocity measure) is beyond the scope of this review, but is easily available.<sup>11,22,23</sup> Motor and sensory EMGs are useful. A sequential technique able to isolate the exact location of the injury along the nerve is recommended (Figure 6). Evoked potentials are not a very useful diagnostic tool.

#### Differential diagnosis

Compression of the brachial plexus between an abnormal<sup>17</sup> cervical rib and the first rib must be eliminated. This pathology gives extensive signs of nerve compression which usually are not limited to the field of the ulnar nerve. Stretching of the brachial plexus is also a possible cause of ulnar nerve palsy, but physical examination and especially an EMG, will help in locating the lesion at the root level.

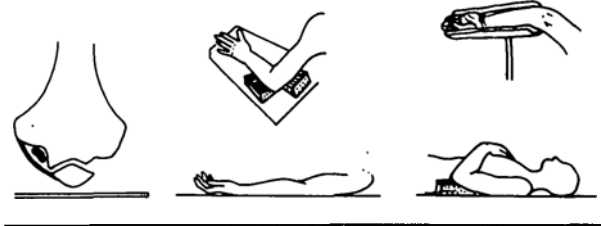


FIGURE 7 Suggested positions to prevent compression on the cubital tunnel. (Adapted from: Wadsworth T.G.<sup>7</sup>)

#### Prevention and treatment

There is no reliable treatment for ulnar nerve palsy. Sometimes external surgical decompression of the nerve in the cubital tunnel<sup>9</sup> permits nerve regeneration. Surgical neurolysis and/or transposition of the ulnar nerve prevent further deterioration particularly in recurrent nerve dislocation.<sup>8</sup> It is difficult to predict which patients will show significant postoperative improvement. Internal neurolysis using saline injection in the nerve is less successful.<sup>9</sup> Usually, treatment is limited to physiotherapy to prevent excessive muscle atrophy while the nerve regenerates with reappearance of motor and sensory activity. Avoidance of further compression is mandatory.

Prevention is the best treatment.<sup>11</sup> Preoperative questioning may, in certain cases, help to discover a preexisting lesion. Careful positioning of every patient on the operating table with proper cushioning of the elbow where there could be compression of the nerve against a hard surface will help to prevent the lesion. Also, placing the arm in supination and avoiding elbow flexion (Figure 7), will free the cubital tunnel. It is recommended to recheck periodically the position of the arm, during long operations or when members of the surgical team are likely to lean on it. The occurrence of postoperative ulnar nerve palsy is difficult to predict: even the most careful positioning is not always sufficient to prevent the lesion. Some patients seem to be prone to this accident in the best of conditions.

#### Conclusion

Postoperative ulnar nerve neuropathy is a serious problem. It is closely related to the cubital tunnel syndrome. Diagnosis is relatively easy with the early use of EMG. Clearly, knowledge and prevention are the best treatments. Scrupulous surveillance of the arm position is mandatory although it is not always successful. Once established, postoperative ulnar neuropathy is difficult to manage and the evolution is unpredictable.

#### Acknowledgement

We thank Christiane Côté for her help in research of bibliography and preparation of the manuscript, and to Sylvie Le Breux for her secretarial assistance.

## References

- 1 *Kroll DA, Caplan RA, Posner K, Ward RJ, Cheney FW.* Nerve injury associated with anesthesia. *Anesthesiology* 1990; 73: 202-7.
- 2 *Alvine FG, Schurrer ME.* Postoperative ulnar-nerve palsy: are there predisposing factors? *J Bone Joint Surg (Am)* 1987; 69-A: 255-9.
- 3 *Ekerot L.* Postanesthetic ulnar neuropathy at the elbow. *Scand J Plast Reconstr Surg* 1977; 11: 225-9.
- 4 *Wey JM, Guinn GA.* Ulnar nerve injury with open-heart surgery. *Ann Thorac Surg* 1985; 39: 358-60.
- 5 *Adriani J.* (Ed.). Peripheral nerve injuries associated with anesthesia and operation. *In: Adriani J (Ed.). Appraisal of Currents in Anesthesiology.* Saint Louis: C.V. Mosby Co., 1964: 412-32.
- 6 *Asbury AK, Johnson PC.* Nerve trauma. *In: Bennington JL (Ed.). Pathology of Peripheral Nerve.* Philadelphia: W.B. Saunders Co., 1978: 198-205.
- 7 *Wadsworth TG.* The external compression syndrome of the ulnar nerve at the cubital tunnel. *Clin Orthop* 1977; 124: 189-204.
- 8 *Childress HM.* Recurrent ulnar-nerve dislocation at the elbow. *J Bone Joint Surg (Am)* 1956; 33-A: 978-84.
- 9 *Wadsworth TG, Williams JR.* Cubital tunnel external compression syndrome. *BMJ* 1973; 662-6.
- 10 *Miller RG.* The cubital tunnel syndrome: diagnosis and precise localization. *Ann Neurol* 1979; 6: 56-9.
- 11 *Miller RG, Camp PE.* Postoperative ulnar neuropathy. *JAMA* 1979; 242: 1636-9.
- 12 *Feindel W, Stratford J.* Cubital tunnel compression in tardy ulnar palsy. *Can Med Assoc J* 1958; 78: 351-3.
- 13 *Staal A.* General discussion on pressure neuropathies. *In: Vinken PJ, Bruyn GW (Eds.). Handbook of Clinical Neurology.* New York: American Elsevier, 1970: 276-84.
- 14 *Hochberg FH, Leffert AD, Heller MD, Merriman L.* Hand difficulties among musicians. *JAMA* 1983; 249: 1869-72.
- 15 *Aita JF.* Postoperative ulnar neuropathy (Letter). *JAMA* 1981; 245: 2295.
- 16 *Strader RP.* Postoperative ulnar neuropathy (Letter). *JAMA* 1980; 243: 1233.
- 17 *Murphy JP, Devers JC.* Prevention of postsurgical ulnar neuropathy. *JAMA* 1974; 227: 1123-4.
- 18 *Nath M, Taylor RG.* Ulnar compression neuropathy: an uncommon complication in surgical repair of pressure ulcers. *Paraplegia* 1978; 16: 370-4.
- 19 *Jones HD.* Ulnar nerve damage following general anaesthetic: a case possibly related to diabetes mellitus. *Anaesthesia* 1967; 22: 471-5.
- 20 *Denny-Brown D, Brenner C.* Paralysis of nerve induced by direct pressure and by tourniquet. *Arch Neurol Psychiat* 1944; 51: 1-26.
- 21 *Ochoa J, Fowler TJ, Gilliat RW.* Anatomical changes in peripheral nerves compressed by a pneumatic tourniquet. *J Anat* 1972; 433-55.
- 22 *Eisen A.* Early diagnosis of ulnar nerve palsy: an electrophysiologic study. *Neurology* 1974; 24: 256-62.
- 23 *Usubiaga JE.* Neurological complications following epidural anesthesia. *Int Anesthesiol Clin* 1975; 13: 85-96.